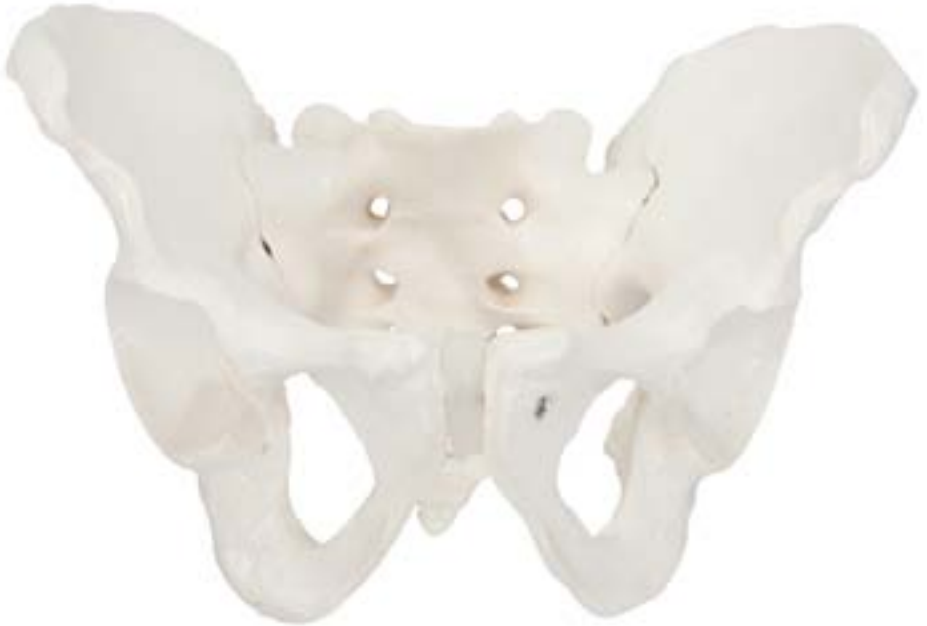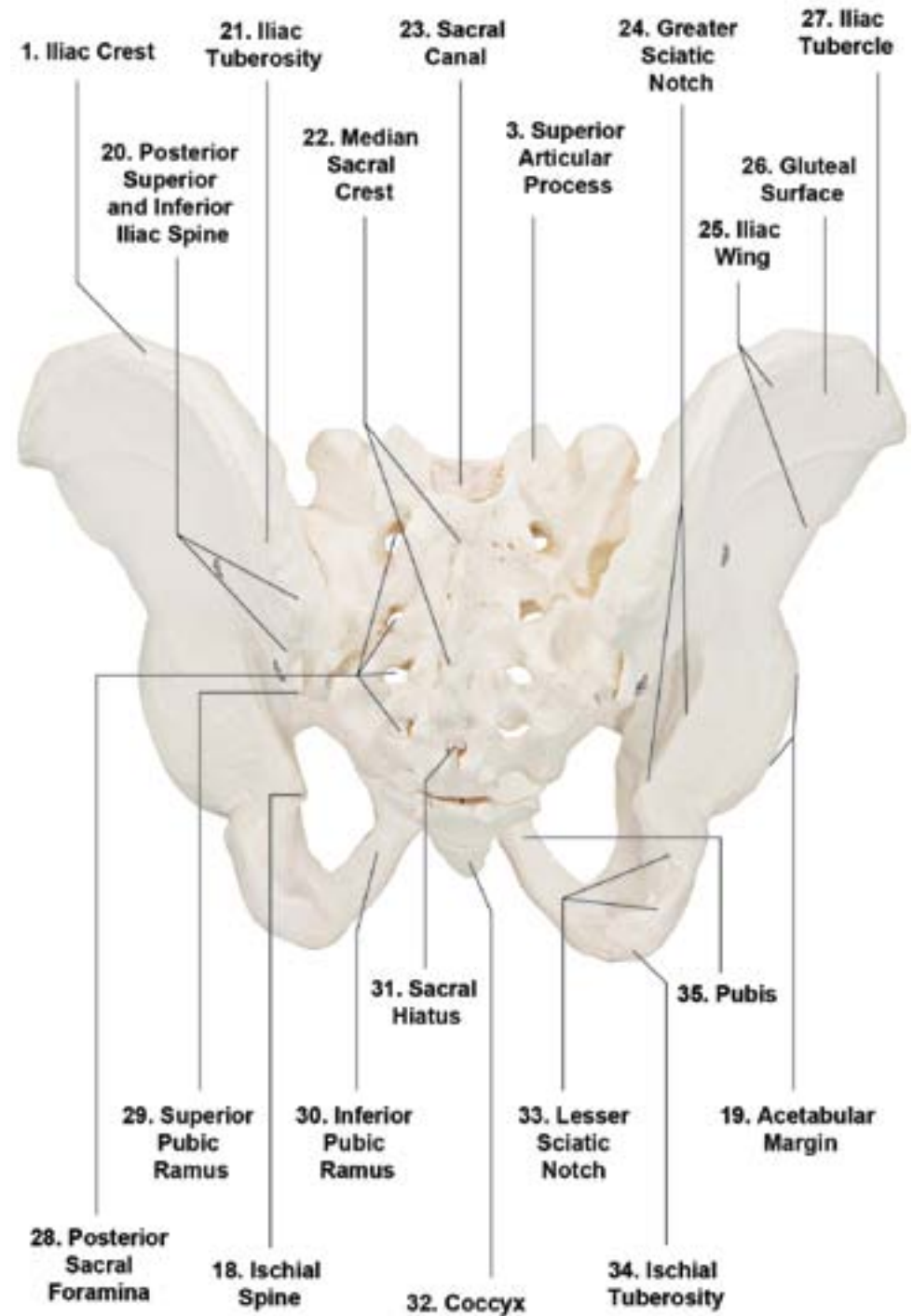




Axis Scientific Male Skeletal Pelvis

A-104275



1. Iliac Crest
2. Sacroiliac Joint
3. Superior Articular Process
4. Promontory
5. Sacrum
6. Acetabulum
7. Anterior Inferior Iliac Spine
8. Iliac Fossa
9. Anterior Superior Iliac Spine
10. Anterior Sacral Foramina
11. Obturator Foramen
12. Superior and Inferior Pubic Rami
13. Coccyx
14. Pubic Symphysis
15. Pubic Tubercle
16. Pecten Pubis
17. Ischial Ramus
18. Ischial Spine
19. Acetabular Margin
20. Posterior Superior and Inferior Iliac Spine
21. Iliac Tuberosity
22. Median Sacral Crest
23. Sacral Canal
24. Greater Sciatic Notch
25. Iliac Wing
26. Gluteal Surface
27. Iliac Tubercle
28. Posterior Sacral Foramina
29. Superior Pubic Ramus
30. Inferior Pubic Ramus
31. Sacral Hiatus
32. Coccyx
33. Lesser Sciatic Notch
34. Ischial Tuberosity
35. Pubis