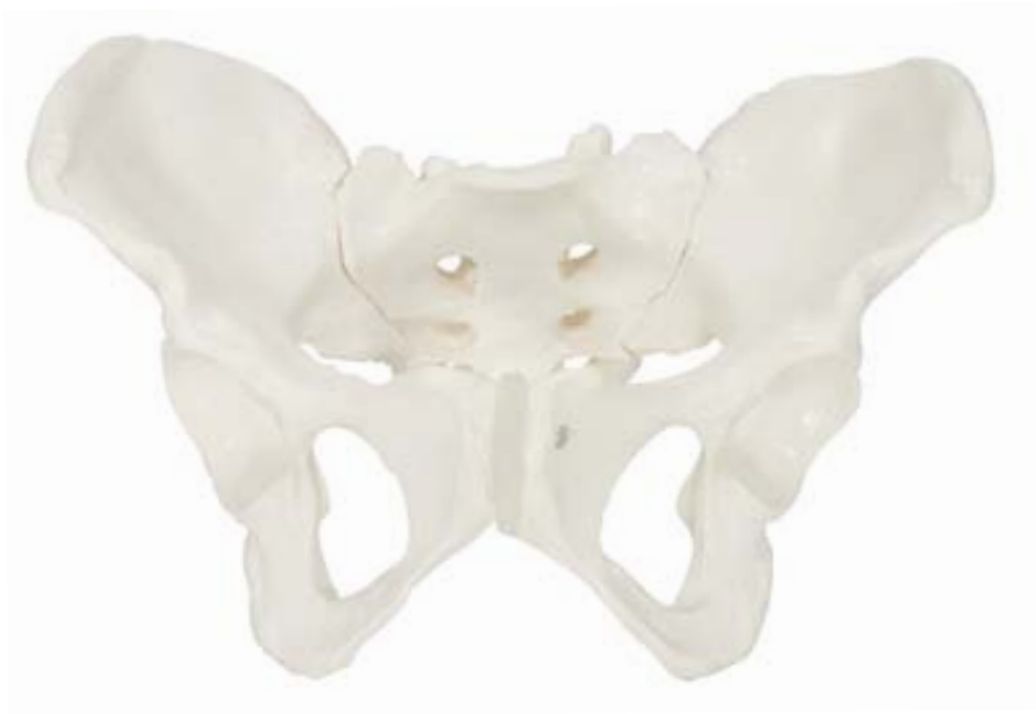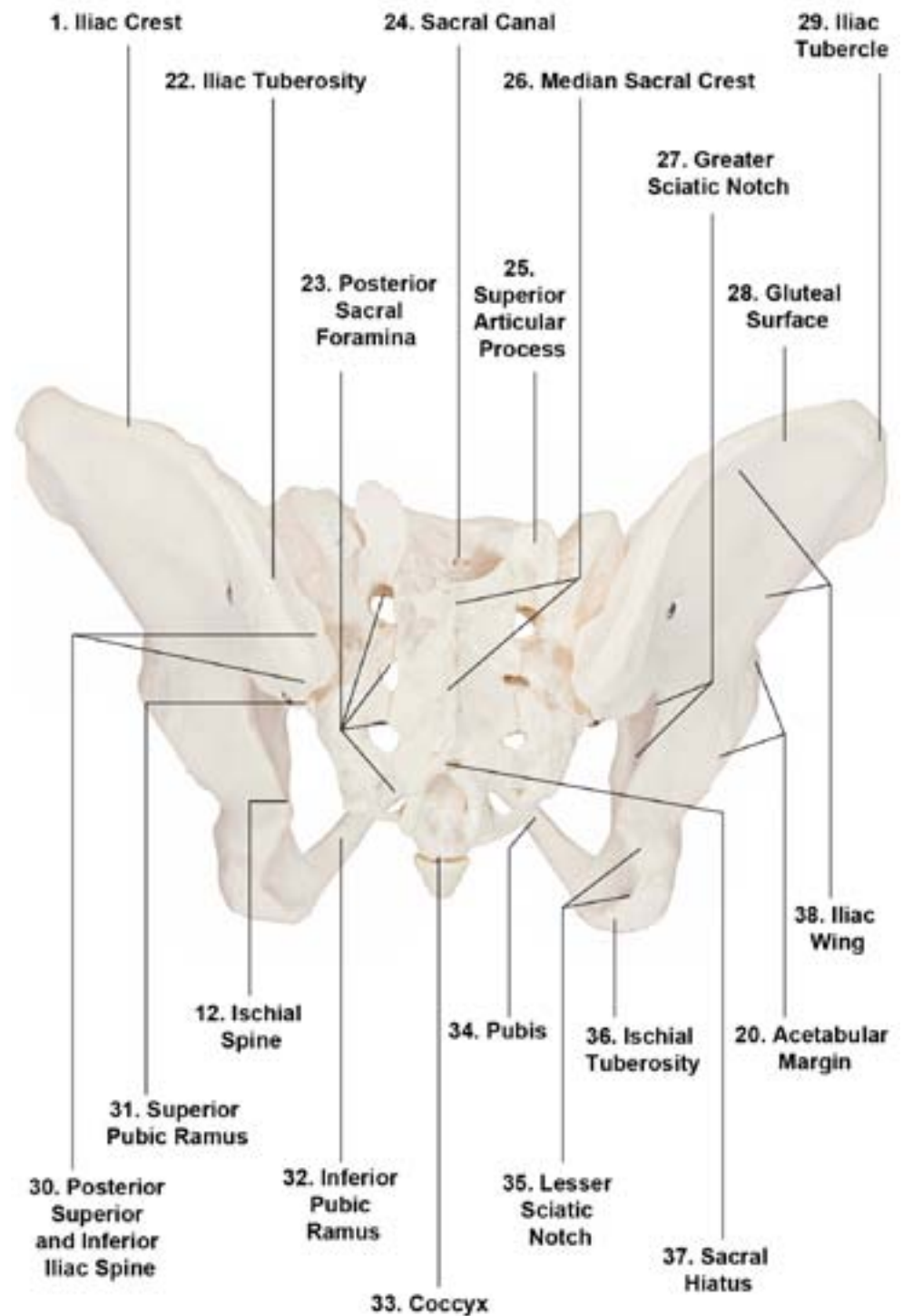
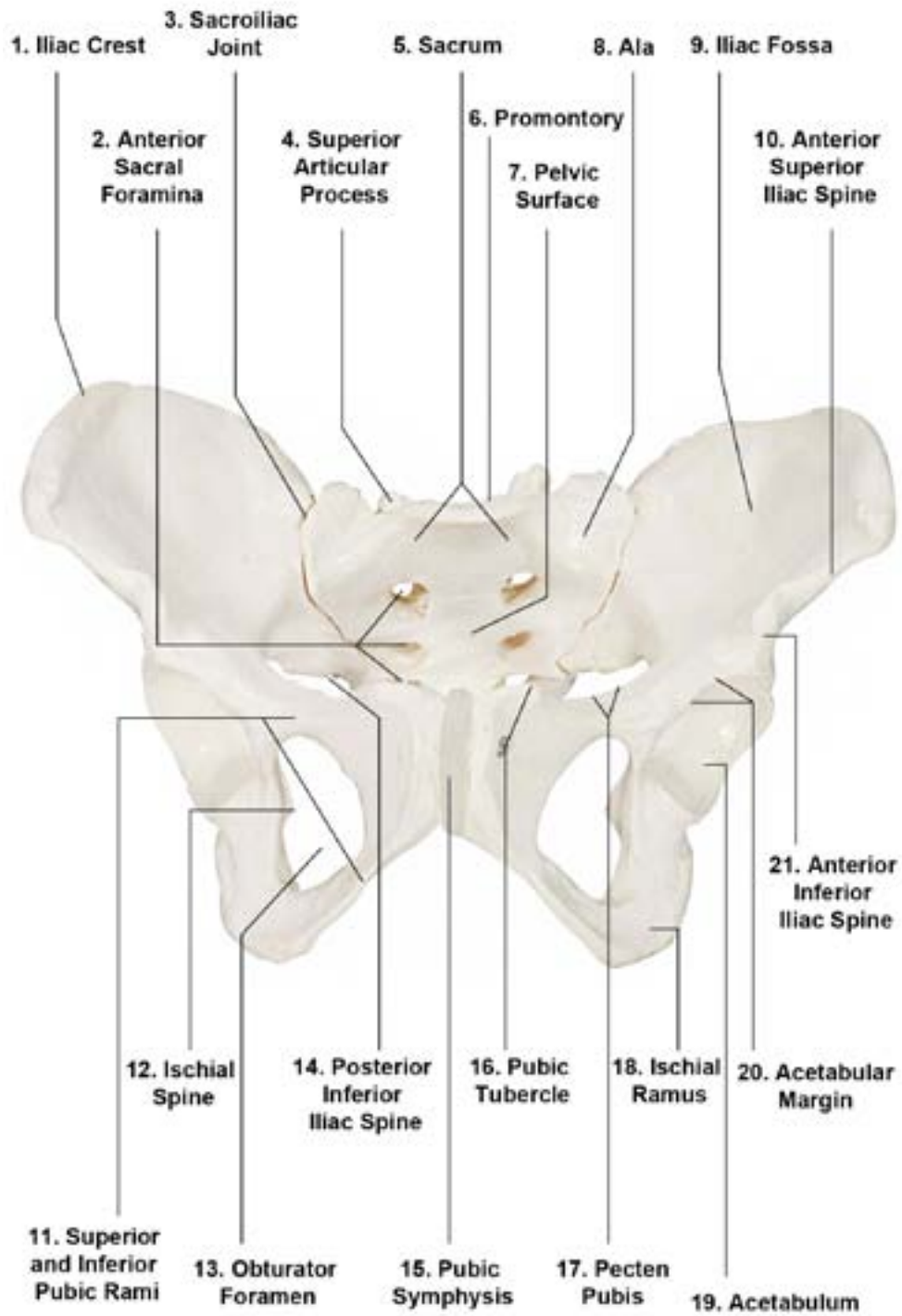




Axis Scientific Female Skeletal Pelvis

A-104276



1. Iliac Crest
2. Anterior Sacral Foramina
3. Sacroiliac Joint
4. Superior Articular Process
5. Sacrum
6. Promontory
7. Pelvic Surface
8. Ala
9. Iliac Fossa
10. Anterior Superior Iliac Spine
11. Superior and Inferior Pubic Rami
12. Ischial Spine
13. Obturator Foramen
14. Posterior Inferior Iliac Spine
15. Pubic Symphysis
16. Pubic Tubercle
17. Pecten Pubis
18. Ischial Ramus
19. Acetabulum
20. Acetabular Margin
21. Anterior Inferior Iliac Spine
22. Iliac Tuberosity
23. Posterior Sacral Foramina
24. Sacral Canal
25. Superior Articular Process
26. Median Sacral Crest
27. Greater Sciatic Notch
28. Gluteal Surface
29. Iliac Tubercle
30. Posterior Superior and Inferior Iliac Spine
31. Superior Pubic Ramus
32. Inferior Pubic Ramus
33. Coccyx
34. Pubis
35. Lesser Sciatic Notch
36. Ischial Tuberosity
37. Sacral Hiatus
38. Iliac Wing