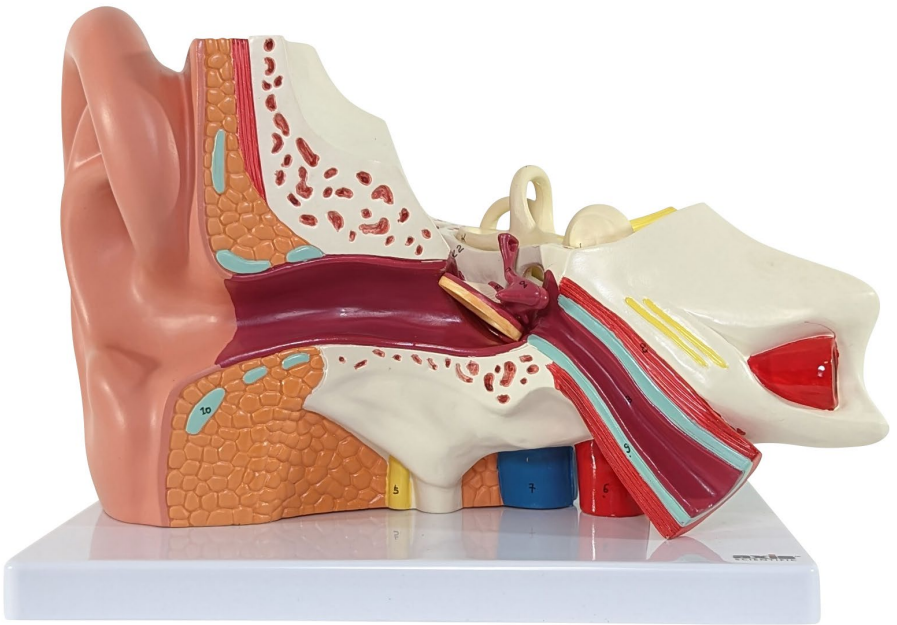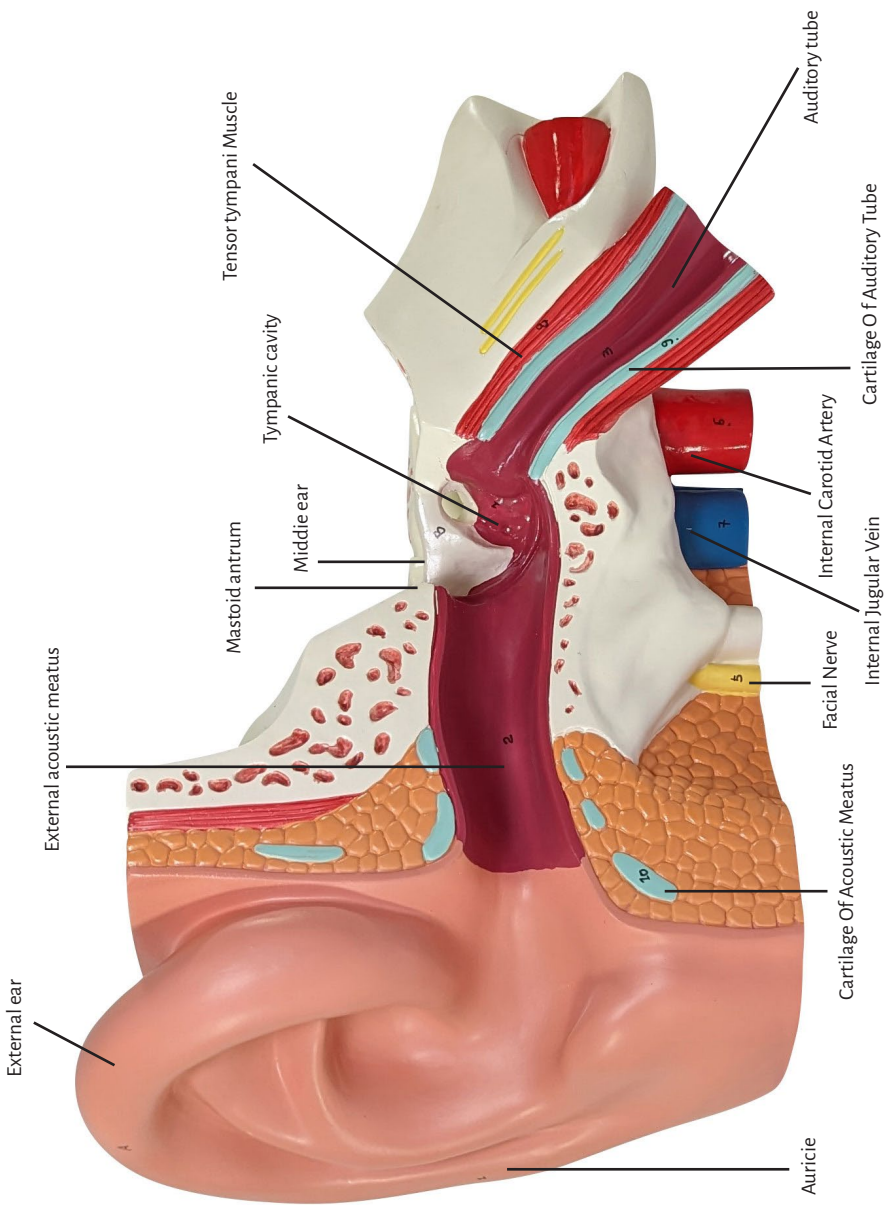
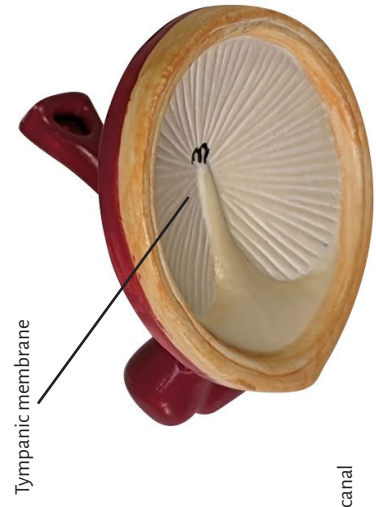




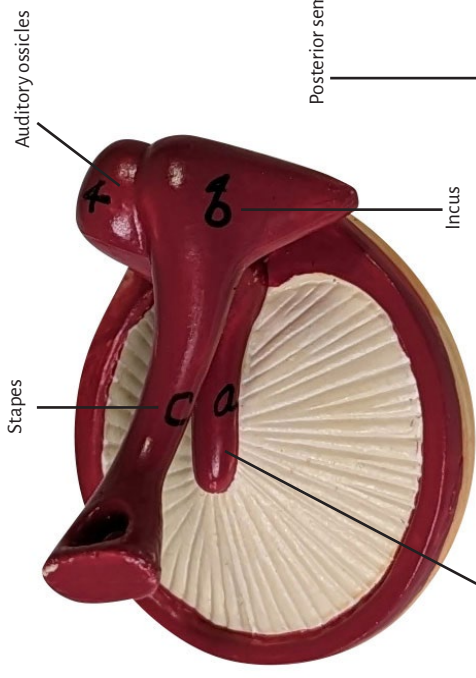
Axis Scientific Oversized 3-Part Human Ear

A-104280





Tympanic membrane

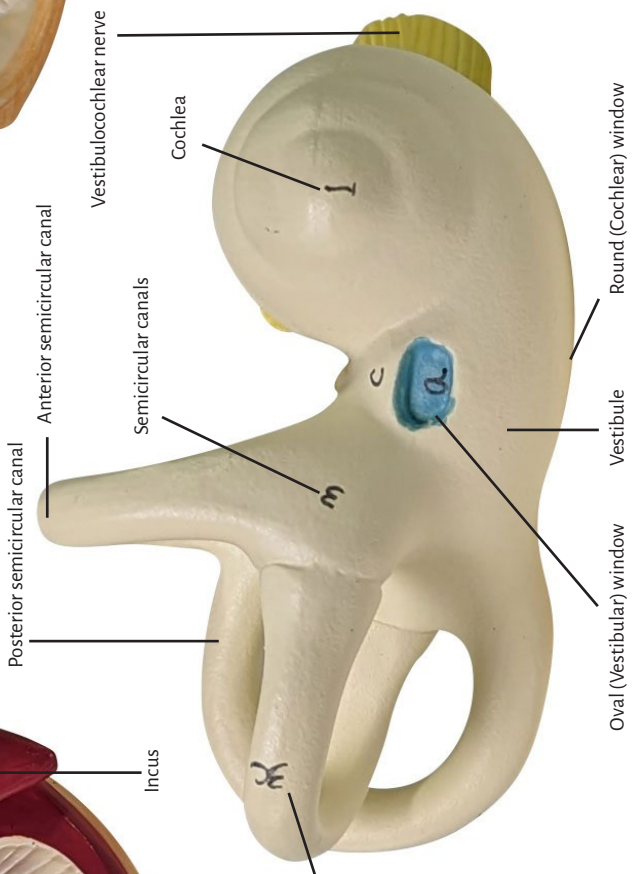


Stapes

Auditory ossicles

Malleus

Incus



Vestibulo-cochlear nerve

Cochlea

Anterior semicircular canal

Semicircular canals

Posterior semicircular canal

Lateral semicircular canal

Round (Cochlear) window

Vestibule

Oval (Vestibular) window

A. External ear

1. Auricle
2. External acoustic meatus
3. Tympanic membrane

B. Middle ear

1. Tympanic cavity
2. Mastoid antrum
3. Auditory tube
4. Auditory ossicles
 - a. Malleus
 - b. Incus
 - c. Stapes

C. Internal ear

1. Cochlea
2. Vestibule
 - a. Oval (Vestibular) window
 - b. Round (Cochlear) window
3. Semicircular canals
 - a. Anterior semicircular canal
 - b. Posterior semicircular canal
 - c. Lateral semicircular canal
4. Vestibulocochlear nerve
5. Facial Nerve
6. Internal Carotid Artery
7. Internal Jugular Vein
8. Tensor tympani Muscle
9. Cartilage Of Auditory Tube
10. Cartilage Of Acoustic Meatus

