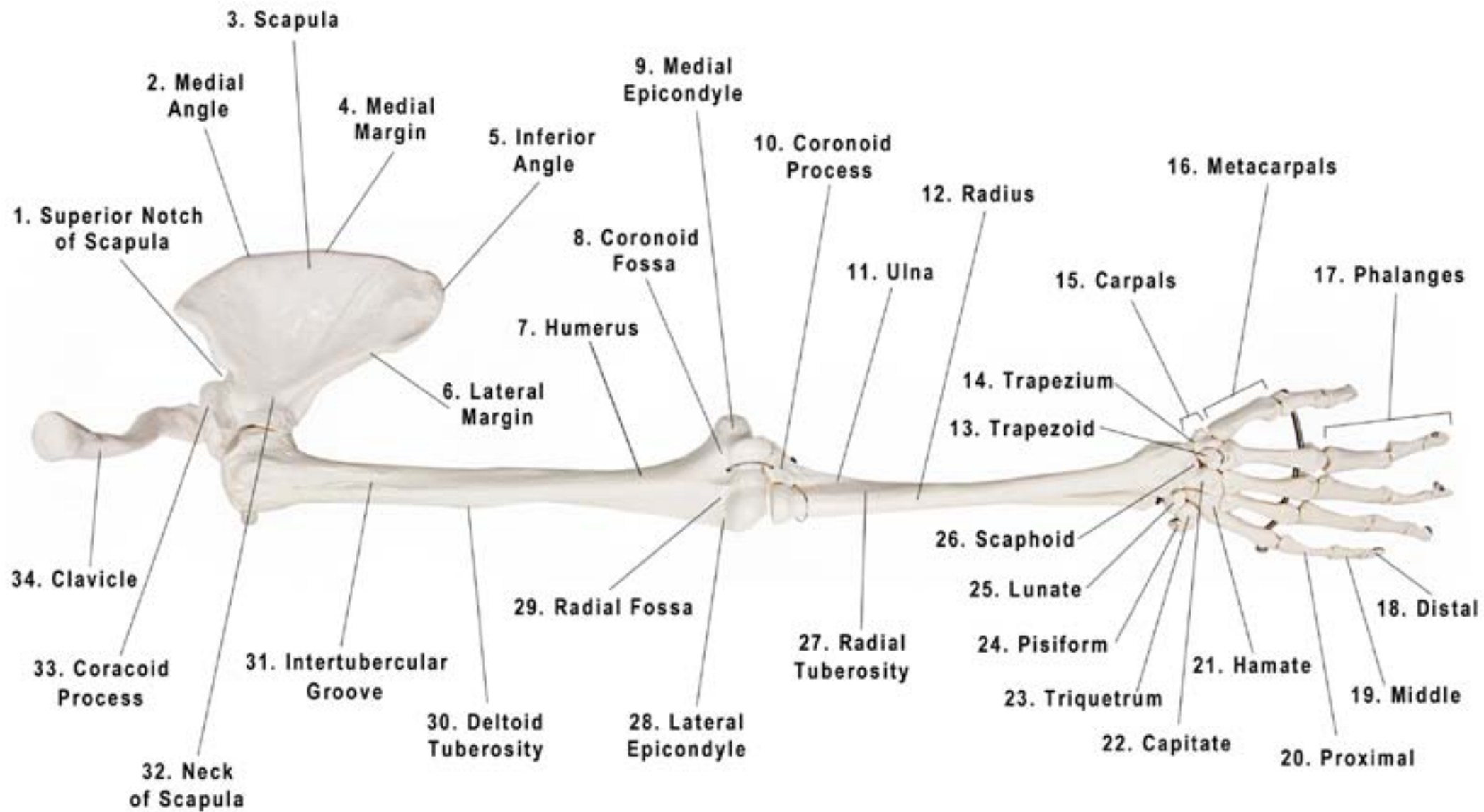




Axis Scientific Arm Skeleton

A-105180



1. Superior Notch of Scapula
2. Medial Angle
3. Scapula
4. Medial Margin
5. Inferior Angle
6. Lateral Margin
7. Humerus
8. Coronoid Fossa
9. Medial Epicondyle
10. Coronoid Process
11. Ulna
12. Radius
13. Trapezoid
14. Trapezium
15. Carpals
16. Metacarpals
17. Phalanges
18. Distal
19. Middle
20. Proximal
21. Hamate
22. Capitate
23. Triquetrum
24. Pisiform
25. Lunate
26. Scaphoid
27. Radial Tuberosity
28. Lateral Epicondyle
29. Radial Fossa
30. Deltoid Tuberosity
31. Intertubercular Groove
32. Neck of Scapula
33. Coracoid Process
34. Clavicle