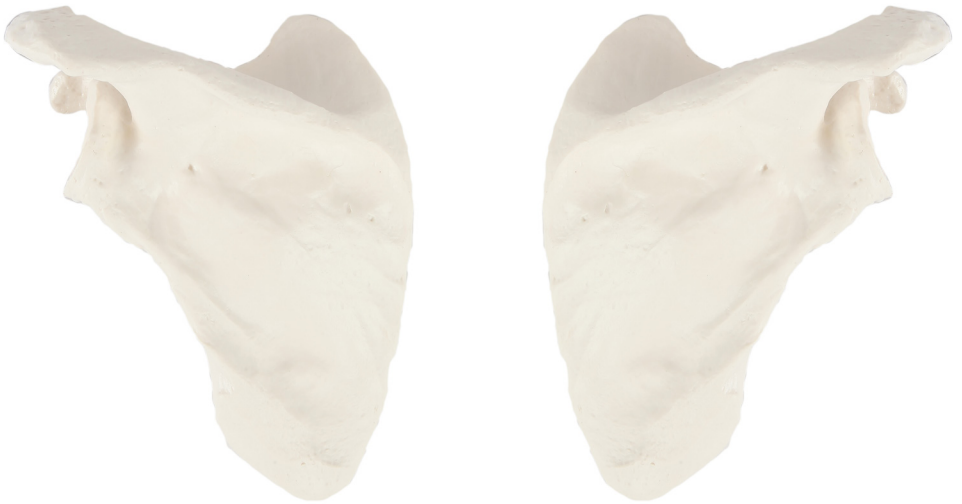
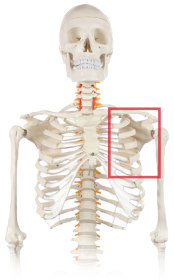
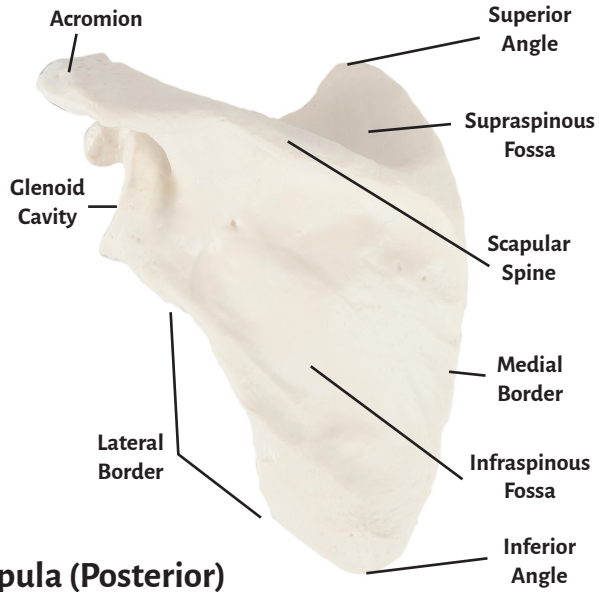


Axis Scientific Scapula Bone

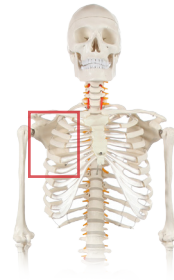A-105639 / A-105640



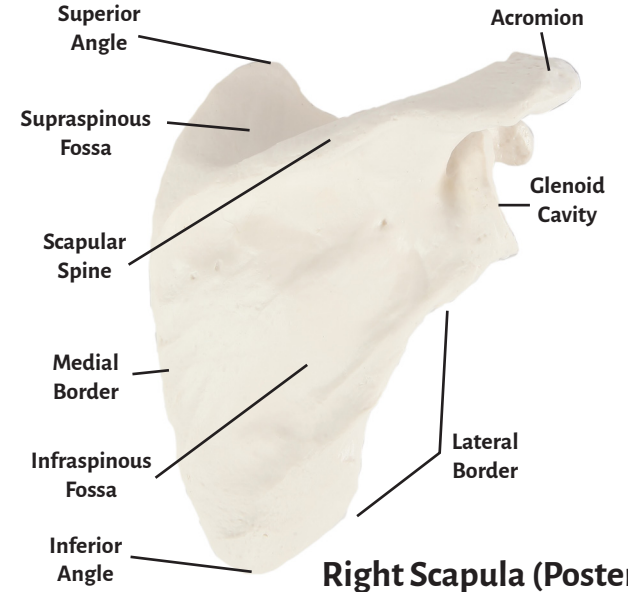
Left Scapula



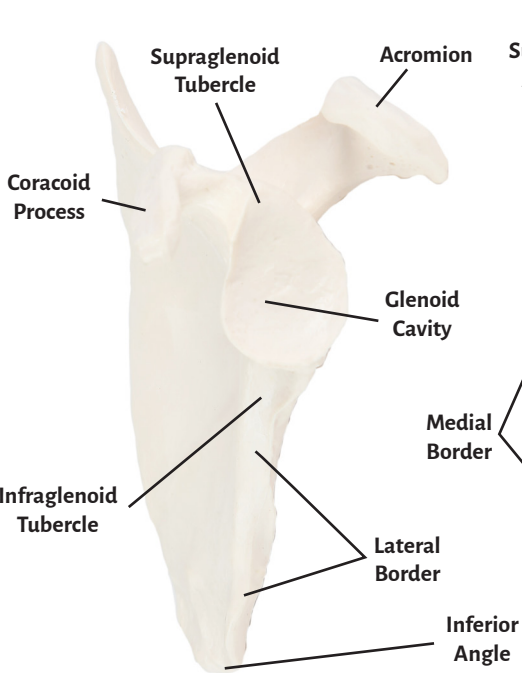
Left Scapula (Posterior)



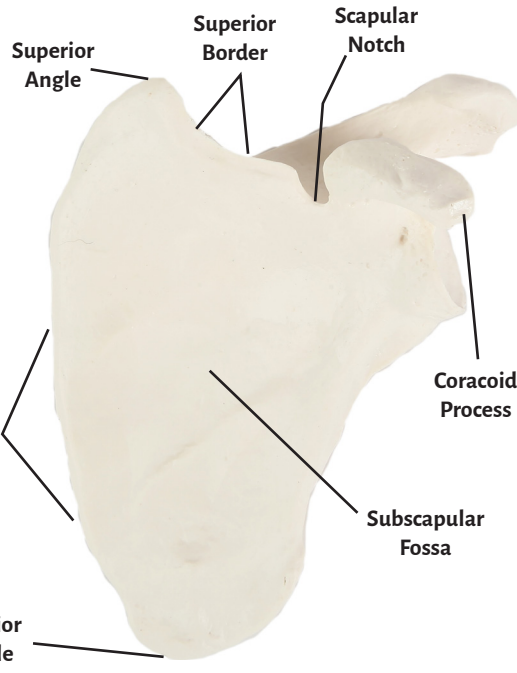
Right Scapula



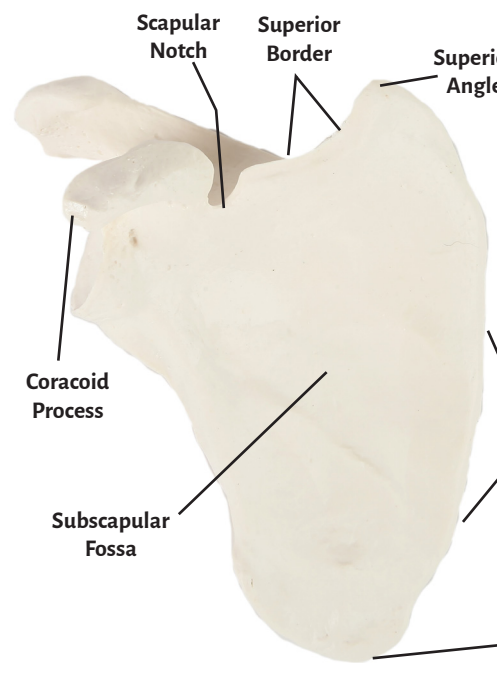
Right Scapula (Posterior)



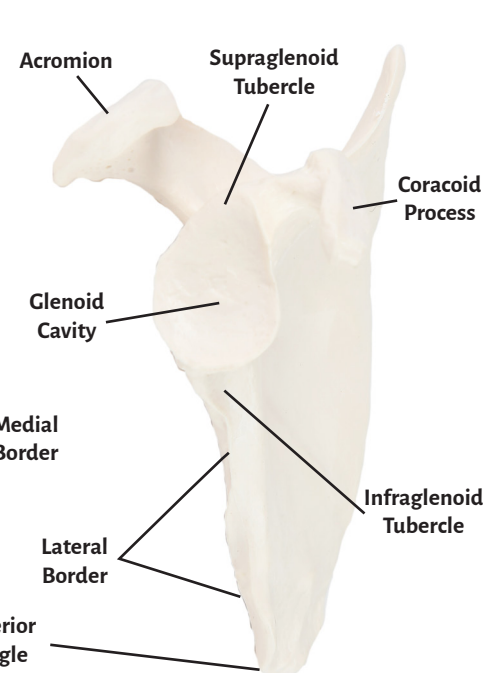
Left Scapula (Lateral)



Left Scapula (Anterior)



Right Scapula



Right Scapula



Acromion

Superior Angle

Supraspinous Fossa

Glenoid Cavity

Scapular Spine

Medial Border

Lateral Border

Subscapular Fossa

Infraspinous Fossa

Inferior Angle

Scapular Notch

Superior Border

Supraglenoid Tubercle

Coracoid Process

Infraglenoid Tubercle

