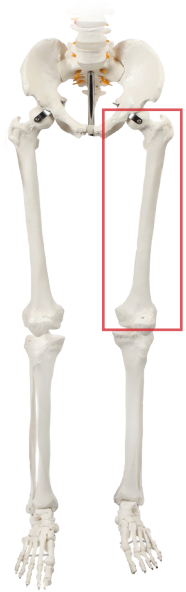


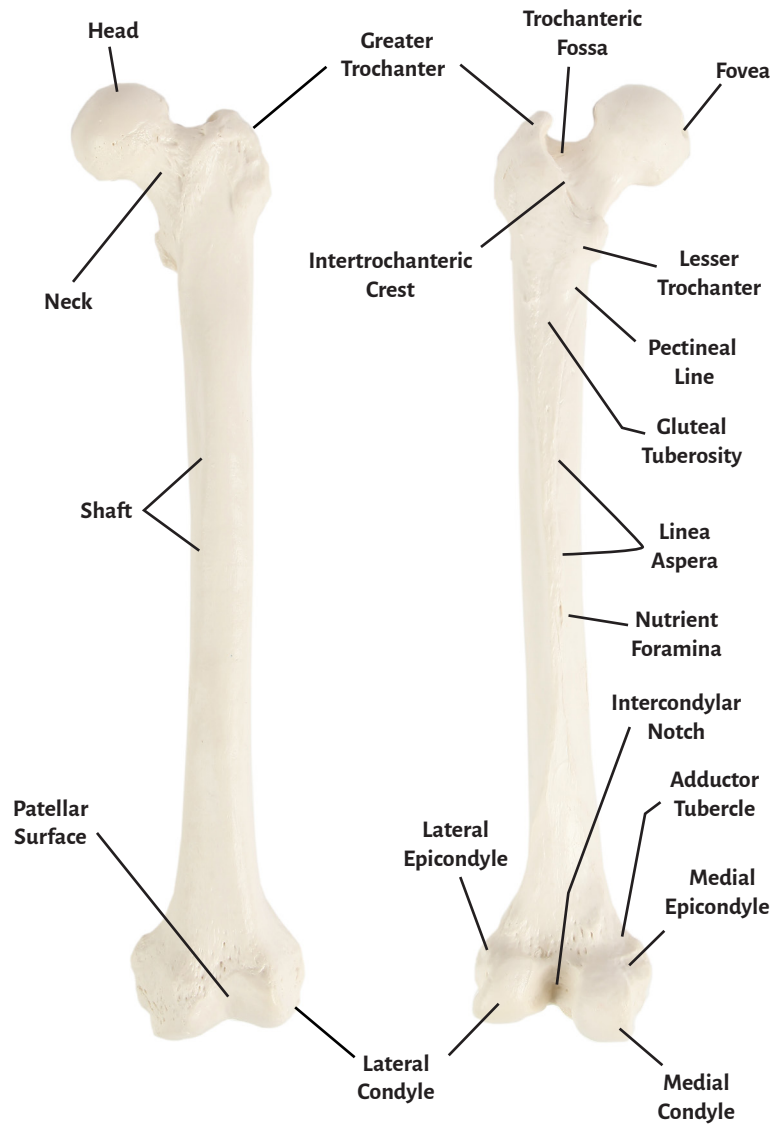


**Axis Scientific Femur Bone**

**A-105660 / A-105661**

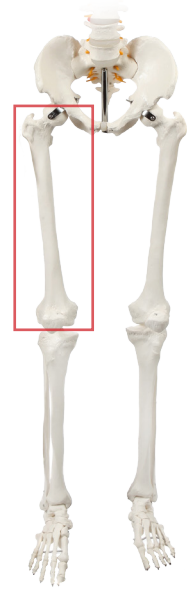


## Left Femur

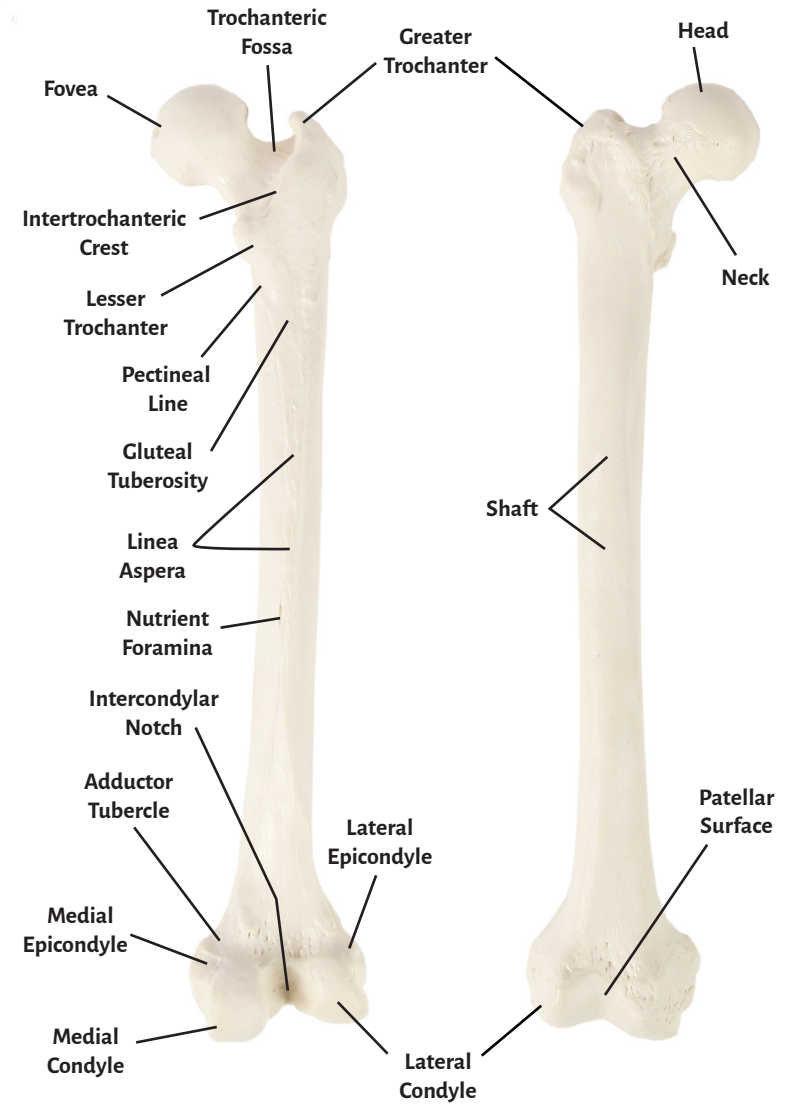


**Anterior**

**Posterior**



## Right Femur



**Posterior**

**Anterior**



<b>Head</b>	<b>Lesser Trochanter</b>
<b>Neck</b>	<b>Intertrochanteric Crest</b>
<b>Fovea</b>	<b>Trochanteric Fossa</b>
<b>Shaft</b>	<b>Pectineal Line</b>
<b>Patellar Surface</b>	<b>Gluteal Tuberosity</b>
<b>Lateral Epicondyle</b>	<b>Linea Aspera</b>
<b>Lateral Condyle</b>	<b>Nutrient Foramina</b>
<b>Medial Epicondyle</b>	<b>Intercondylar Notch</b>
<b>Medial Condyle</b>	<b>Adductor Tubercle</b>

