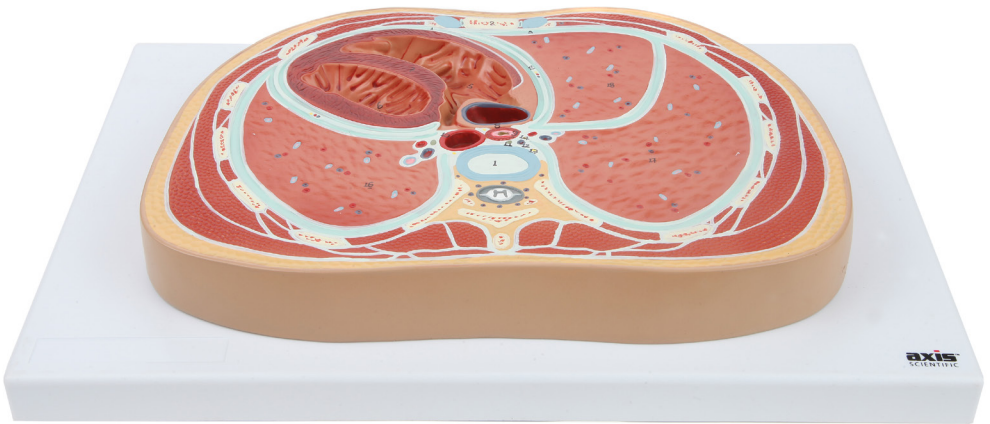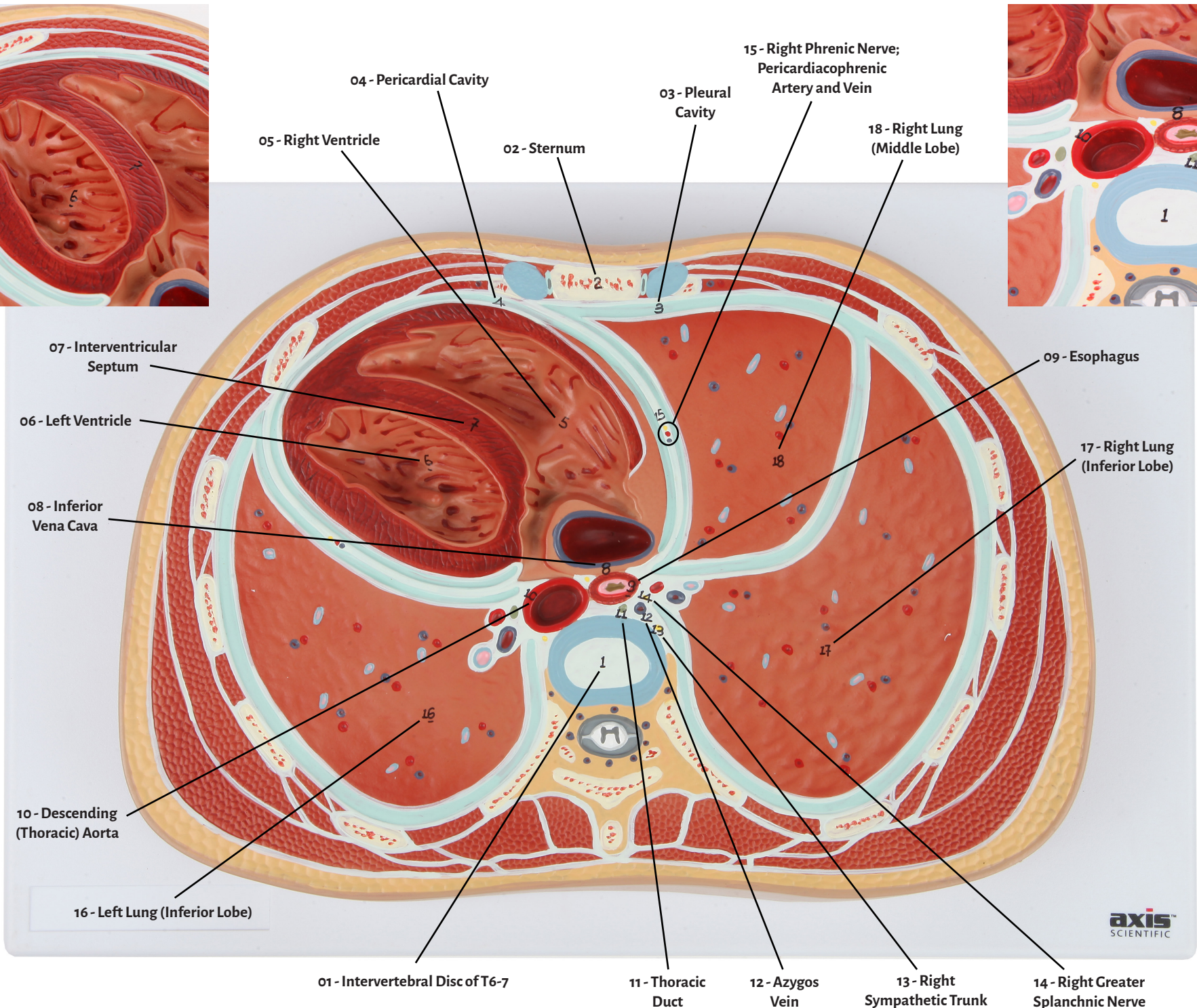
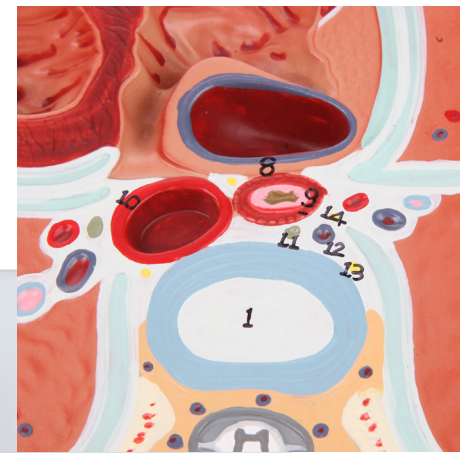
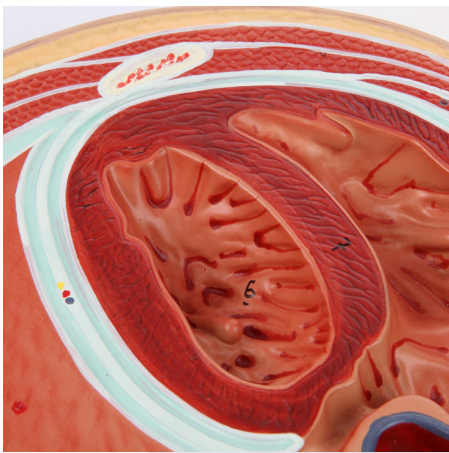


Axis Scientific Abdominal Cross Section at T6

A-105860



- 01 - Intervertebral Disc of T6-7
- 02 - Sternum
- 03 - Pleural Cavity
- 04 - Pericardial Cavity
- 05 - Right Ventricle
- 06 - Left Ventricle
- 07 - Interventricular Septum
- 08 - Inferior Vena Cava
- 09 - Esophagus
- 10 - Descending (Thoracic) Aorta
- 11 - Thoracic Duct
- 12 - Azygos Vein
- 13 - Right Sympathetic Trunk
- 14 - Right Greater Splanchnic Nerve
- 15 - Right Phrenic Nerve; Pericardiophrenic Artery and Vein
- 16 - Left Lung (Inferior Lobe)
- 17 - Right Lung (Inferior Lobe)
- 18 - Right Lung (Middle Lobe)



01 - Intervertebral Disc of T6-7

10 - Descending (Thoracic) Aorta

02 - Sternum

11 - Thoracic Duct

03 - Pleural Cavity

12 - Azygos Vein

04 - Pericardial Cavity

13 - Right Sympathetic Trunk

05 - Right Ventricle

14 - Right Greater Splanchnic Nerve

06 - Left Ventricle

15 - Right Phrenic Nerve;
Pericardiophrenic
Artery and Vein

07 - Interventricular Septum

16 - Left Lung (Inferior Lobe)

08 - Inferior Vena Cava

17 - Right Lung (Inferior Lobe)

09 - Esophagus

18 - Right Lung (Middle Lobe)

