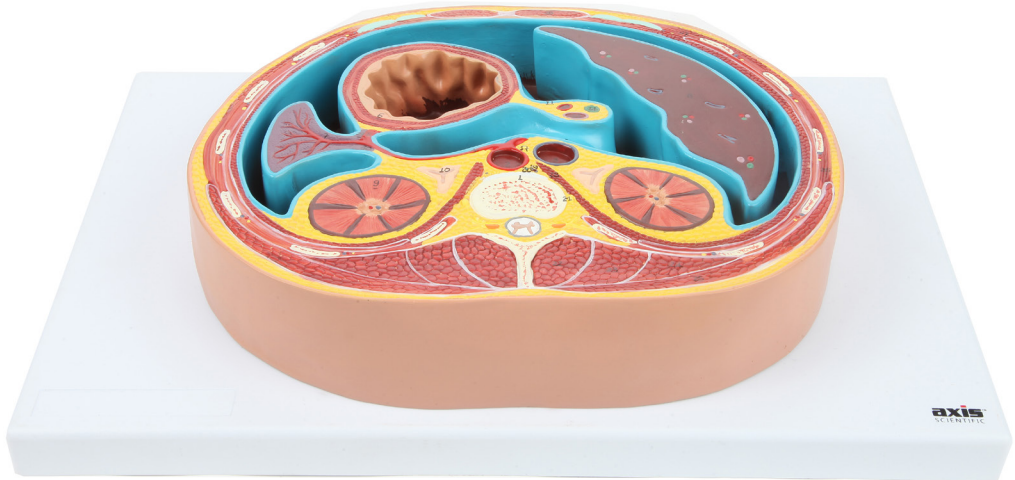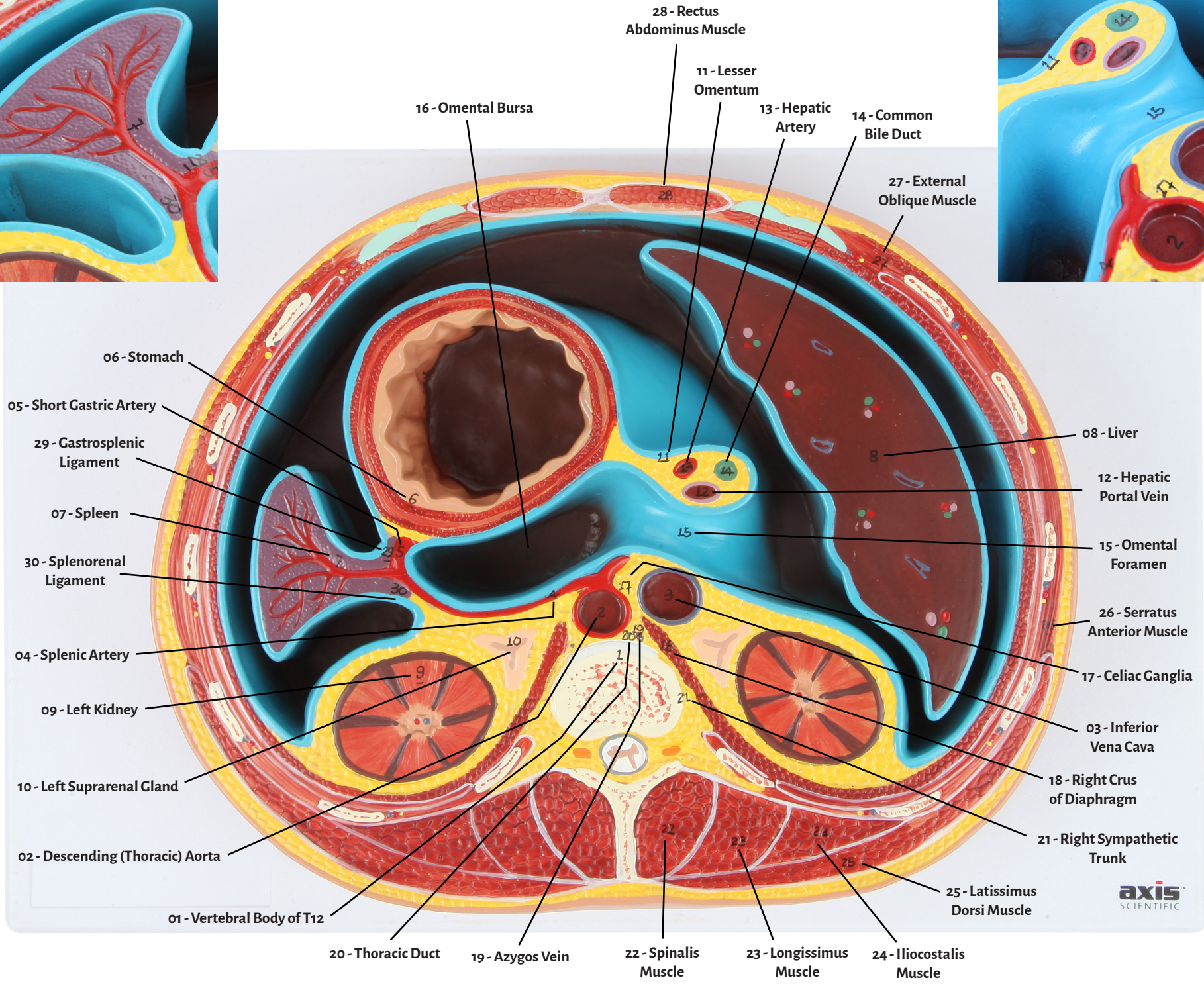

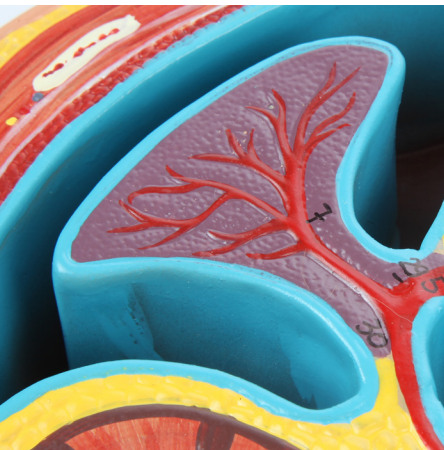
Axis Scientific Abdominal Cross Section at T12

A-105861





- | | |
|----------------------------------|-------------------------------|
| 01 - Vertebral Body of T12 | 16 - Omental Bursa |
| 02 - Descending (Thoracic) Aorta | 17 - Celiac Ganglia |
| 03 - Inferior Vena Cava | 18 - Right Crus of Diaphragm |
| 04 - Splenic Artery | 19 - Azygos Vein |
| 05 - Short Gastric Artery | 20 - Thoracic Duct |
| 06 - Stomach | 21 - Right Sympathetic Trunk |
| 07 - Spleen | 22 - Spinalis Muscle |
| 08 - Liver | 23 - Longissimus Muscle |
| 09 - Left Kidney | 24 - Iliocostalis Muscle |
| 10 - Left Suprarenal Gland | 25 - Latissimus Dorsi Muscle |
| 11 - Lesser Omentum | 26 - Serratus Anterior Muscle |
| 12 - Hepatic Portal Vein | 27 - External Oblique Muscle |
| 13 - Hepatic Artery | 28 - Rectus Abdominus Muscle |
| 14 - Common Bile Duct | 29 - Gastrosplenic Ligament |
| 15 - Omental Foramen | 30 - Splenorenal Ligament |

