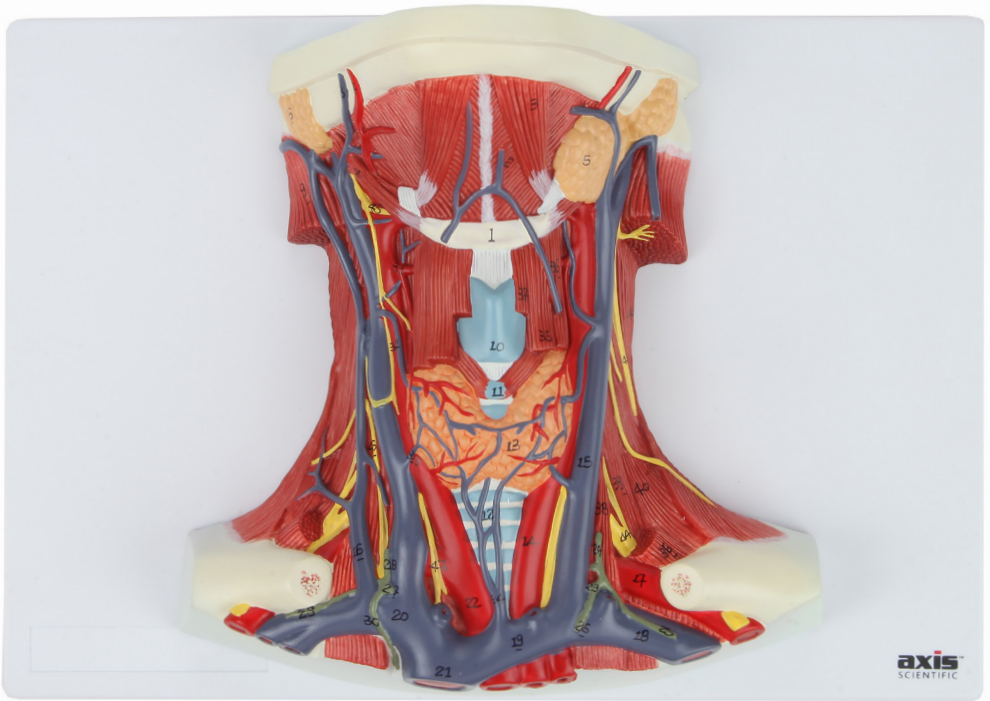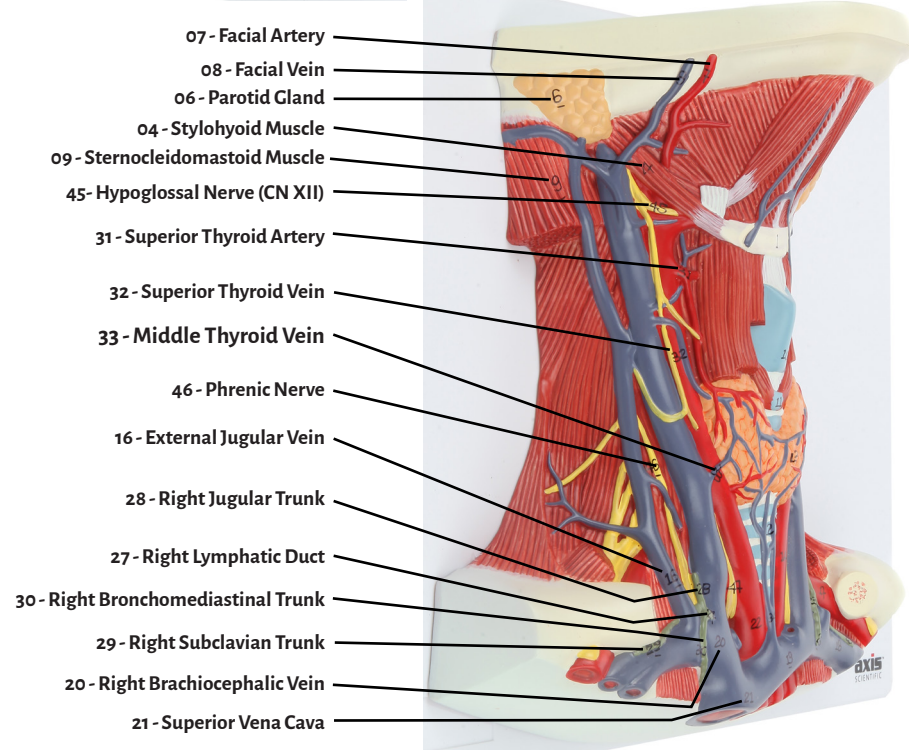
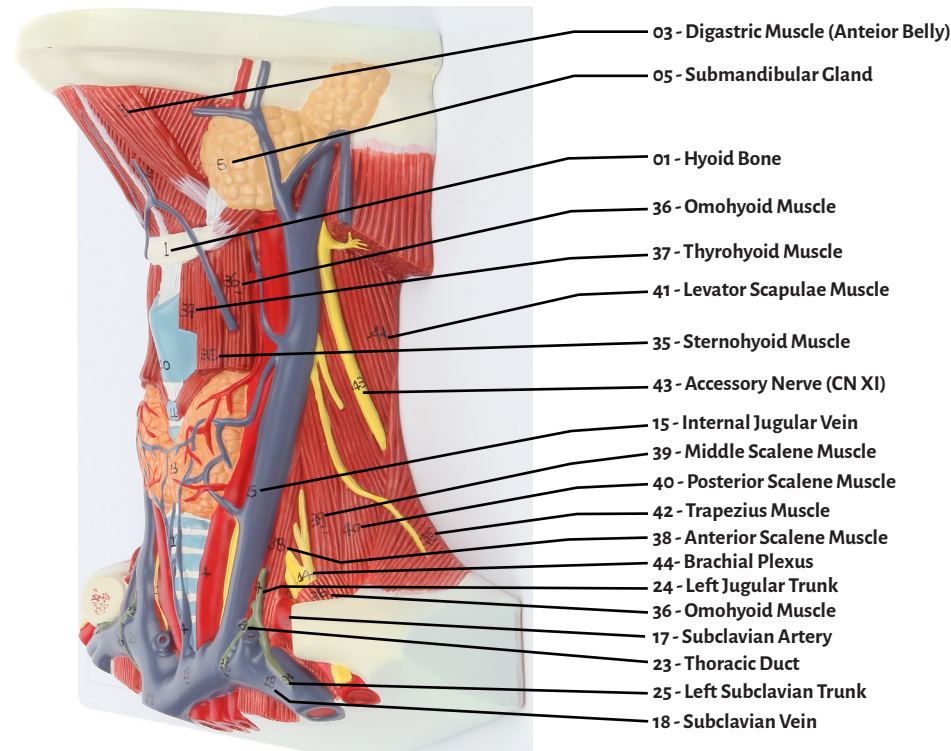
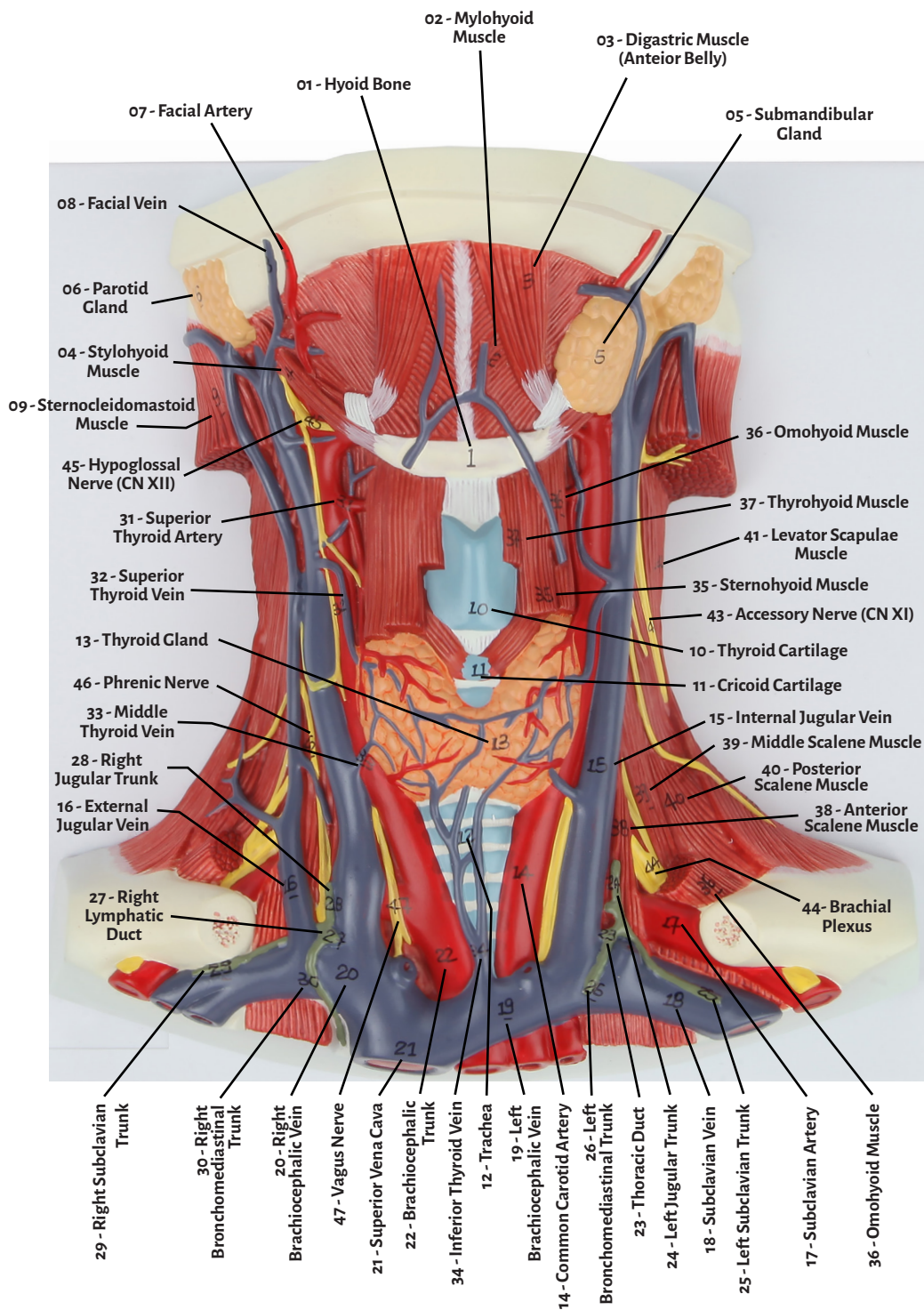




Axis Scientific Neck & Throat Muscles, Arteries, and Veins

A-105862





- 01 - Hyoid Bone
- 02 - Mylohyoid Muscle
- 03 - Digastric Muscle (Anterior Belly)
- 04 - Stylohyoid Muscle
- 05 - Submandibular Gland
- 06 - Parotid Gland
- 07 - Facial Artery
- 08 - Facial Vein
- 09 - Sternocleidomastoid Muscle
- 10 - Thyroid Cartilage
- 11 - Cricoid Cartilage
- 12 - Trachea
- 13 - Thyroid Gland
- 14 - Common Carotid Artery
- 15 - Internal Jugular Vein
- 16 - External Jugular Vein
- 17 - Subclavian Artery
- 18 - Subclavian Vein
- 19 - Left Brachiocephalic Vein
- 20 - Right Brachiocephalic Vein
- 21 - Superior Vena Cava
- 22 - Brachiocephalic Trunk
- 23 - Thoracic Duct
- 24 - Left Jugular Trunk
- 25 - Left Subclavian Trunk
- 26 - Left Bronchomediastinal Trunk
- 27 - Right Lymphatic Duct
- 28 - Right Jugular Trunk
- 29 - Right Subclavian Trunk
- 30 - Right Bronchomediastinal Trunk
- 31 - Superior Thyroid Artery
- 32 - Superior Thyroid Vein
- 33 - Middle Thyroid Vein
- 34 - Inferior Thyroid Vein
- 34 - Inferior Thyroid Vein
- 35 - Sternohyoid Muscle
- 36 - Omohyoid Muscle
- 37 - Thyrohyoid Muscle
- 38 - Anterior Scalene Muscle
- 39 - Middle Scalene Muscle
- 40 - Posterior Scalene Muscle
- 41 - Levator Scapulae Muscle
- 42 - Trapezius Muscle
- 43 - Accessory Nerve (CN XI)
- 44 - Brachial Plexus
- 45 - Hypoglossal Nerve (CN XII)
- 46 - Phrenic Nerve
- 47 - Vagus Nerve

