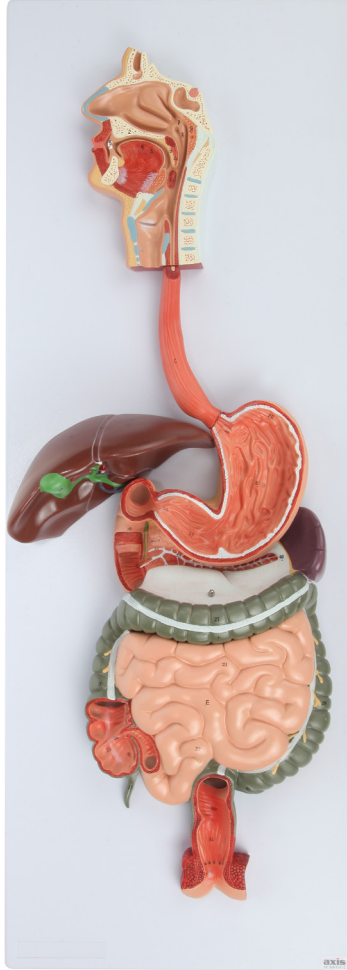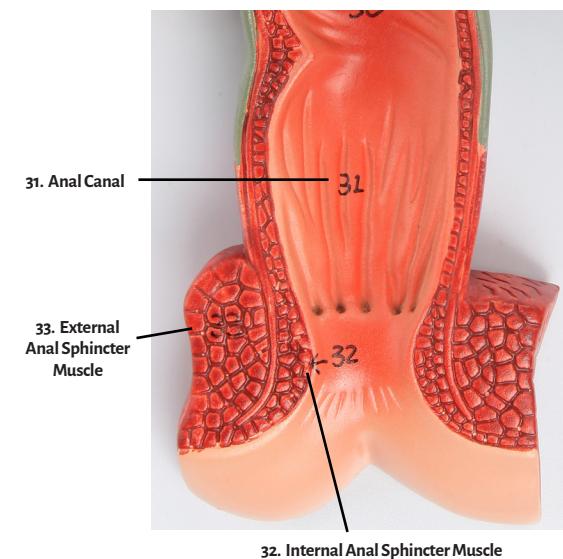
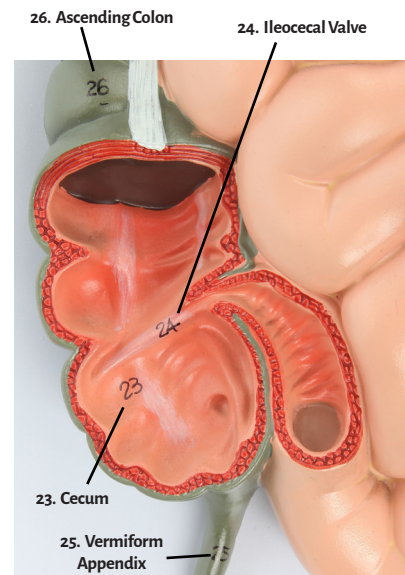
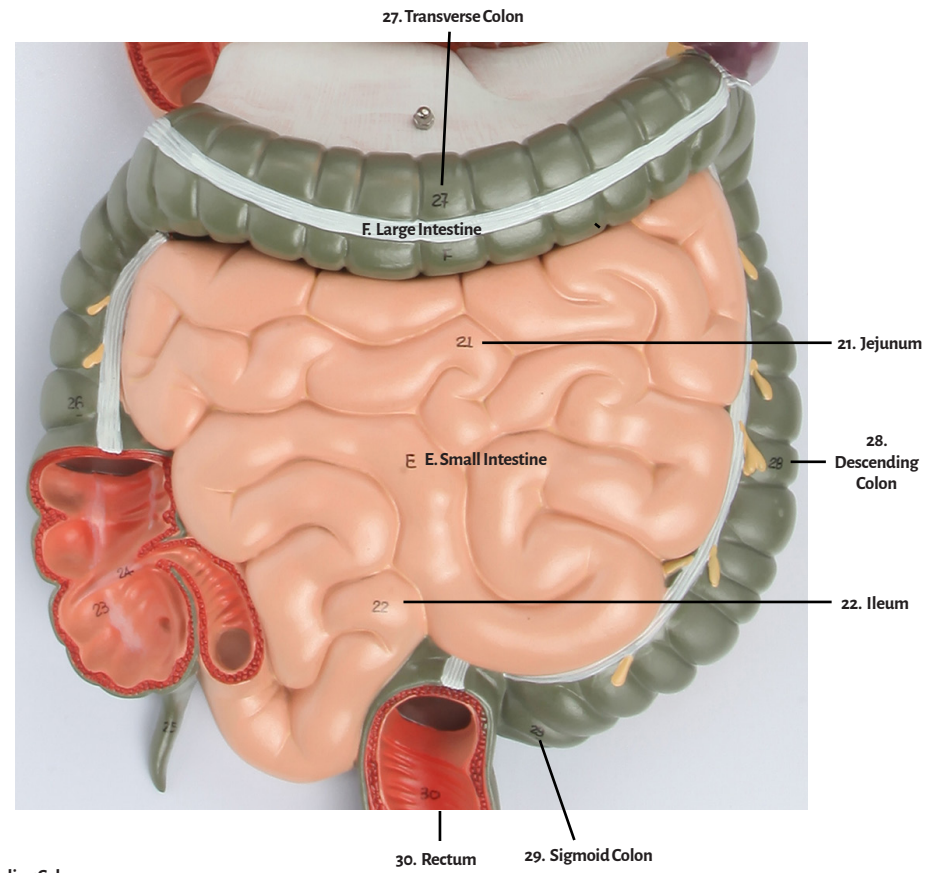
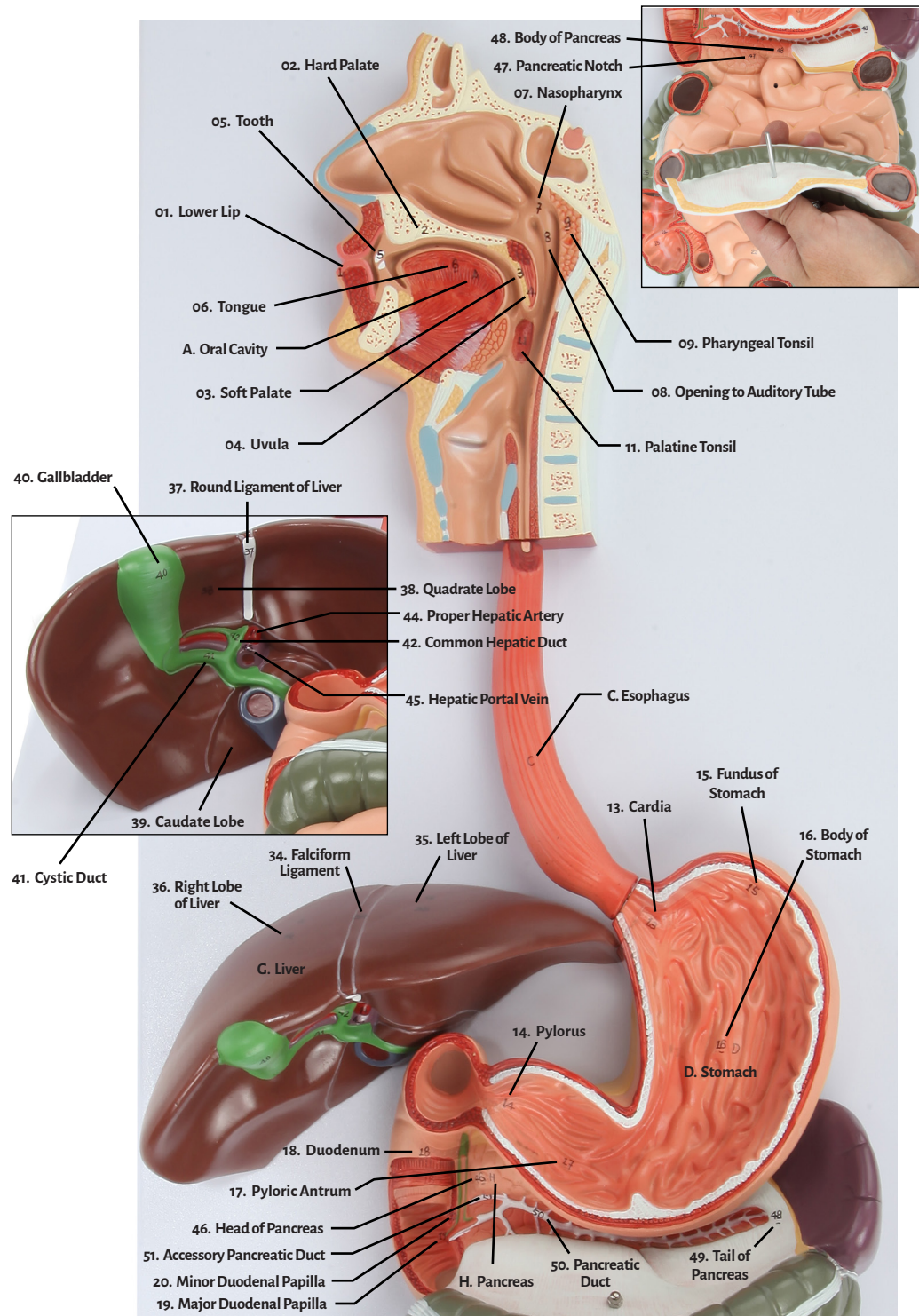




Axis Scientific Human Digestive System (1/2 Size)

A-105865





- | | | |
|------------------------------|------------------------------------|-------------------------------|
| 01. Lower Lip | 20. Minor Duodenal Papilla | 39. Caudate Lobe |
| 02. Hard Palate | 21. Jejunum | 40. Gallbladder |
| 03. Soft Palate | 22. Ileum | 41. Cystic Duct |
| 04. Uvula | 23. Cecum | 42. Common Hepatic Duct |
| 05. Tooth | 24. Ileocecal Valve | 43. Common Bile Duct |
| 06. Tongue | 25. Vermiform Appendix | 44. Proper Hepatic Artery |
| 07. Nasopharynx | 26. Ascending Colon | 45. Hepatic Portal Vein |
| 08. Opening to Auditory Tube | 27. Transverse Colon | 46. Head of Pancreas |
| 09. Pharyngeal Tonsil | 28. Descending Colon | 47. Pancreatic Notch |
| 10. Oropharynx | 30. Rectum | 48. Body of Pancreas |
| 11. Palatine Tonsil | 29. Sigmoid Colon | 49. Tail of Pancreas |
| 12. Laryngopharynx | 31. Anal Canal | 50. Pancreatic Duct |
| 13. Cardia | 32. Internal Anal Sphincter Muscle | 51. Accessory Pancreatic Duct |
| 14. Pylorus | 33. External Anal Sphincter Muscle | A. Oral Cavity |
| 15. Fundus of Stomach | 34. Falciform Ligament | B. Pharynx |
| 16. Body of Stomach | 35. Left Lobe of Liver | C. Esophagus |
| 17. Pyloric Antrum | 36. Right Lobe of Liver | D. Stomach |
| 18. Duodenum | 37. Round Ligament of Liver | E. Small Intestine |
| 19. Major Duodenal Papilla | 38. Quadrate Lobe | F. Large Intestine |
| | | G. Liver |
| | | H. Pancreas |

