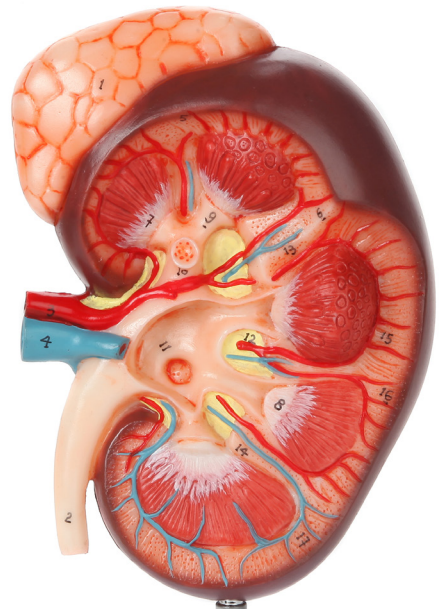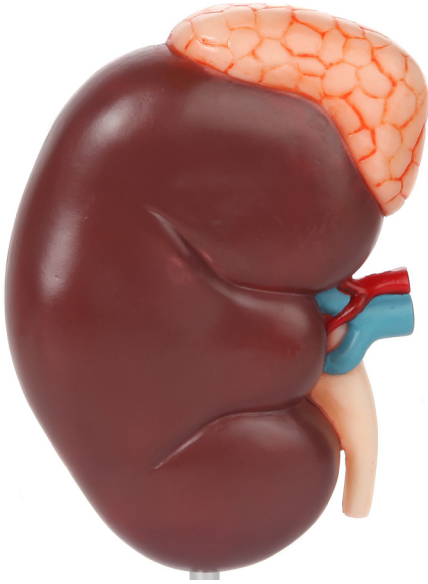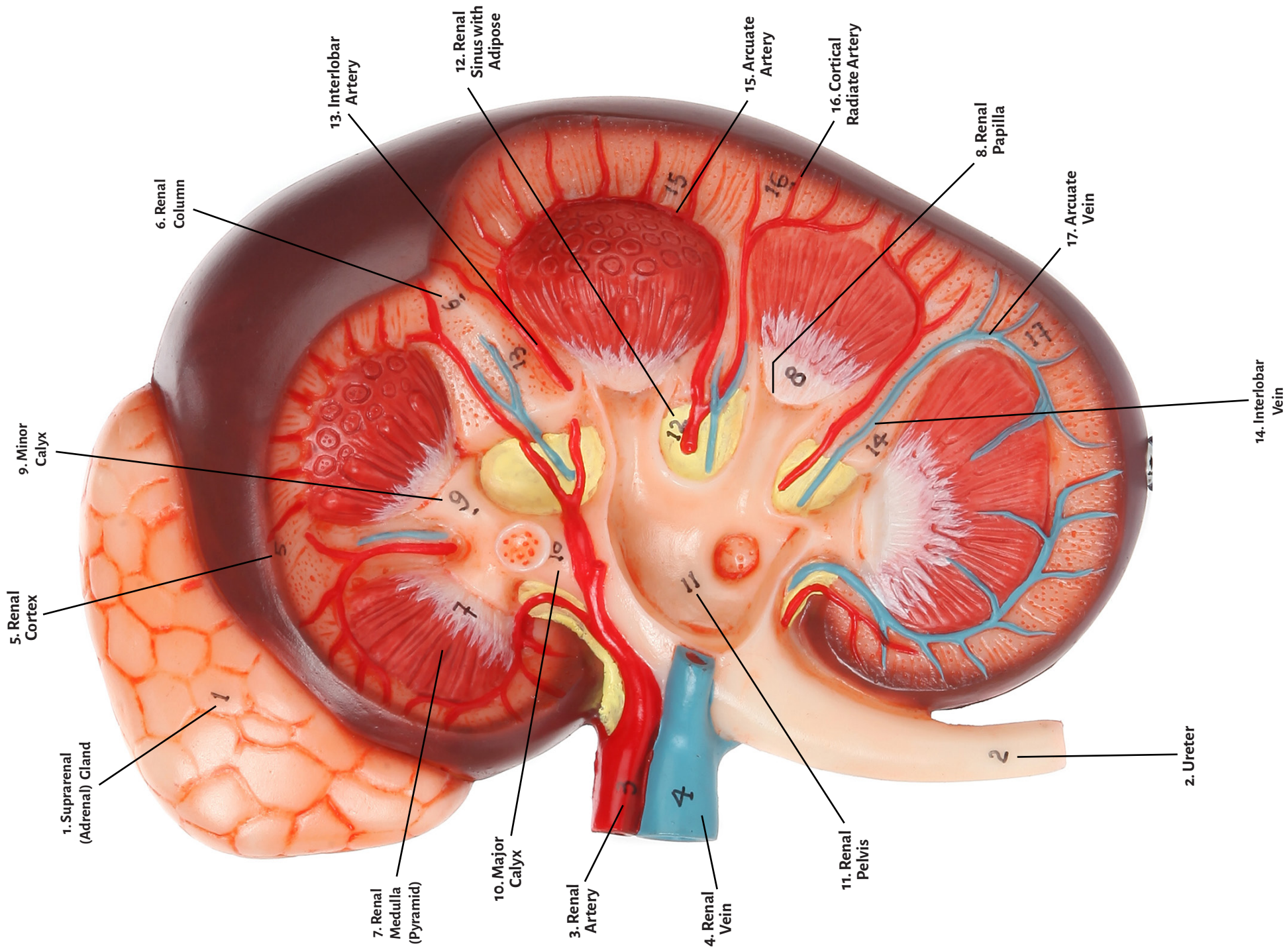


Axis Scientific Kidney with Suprarenal Gland

A-105870





1. Suprarenal (Adrenal) Gland

10. Major Calyx

2. Ureter

11. Renal Pelvis

3. Renal Artery

12. Renal Sinus with Adipose

4. Renal Vein

13. Interlobar Artery

5. Renal Cortex

14. Interlobar Vein

6. Renal Column

15. Arcuate Artery

7. Renal Medulla (Pyramid)

16. Cortical Radiate Artery

8. Renal Papilla

9. Minor Calyx

17. Arcuate Vein

