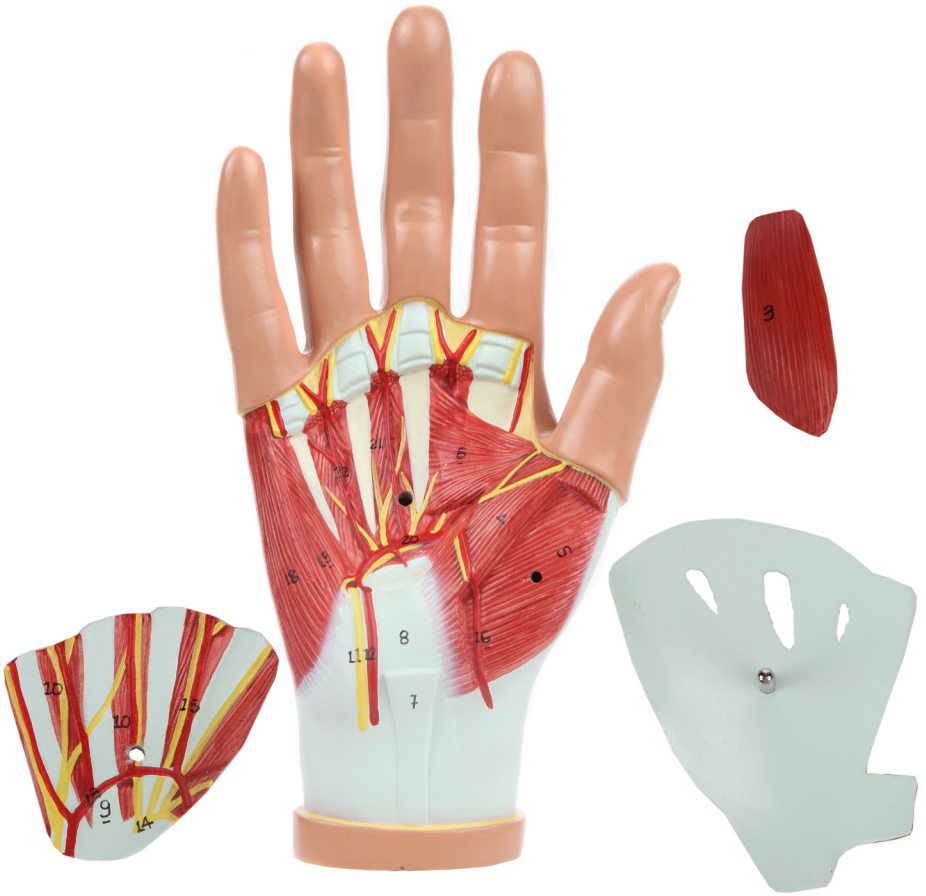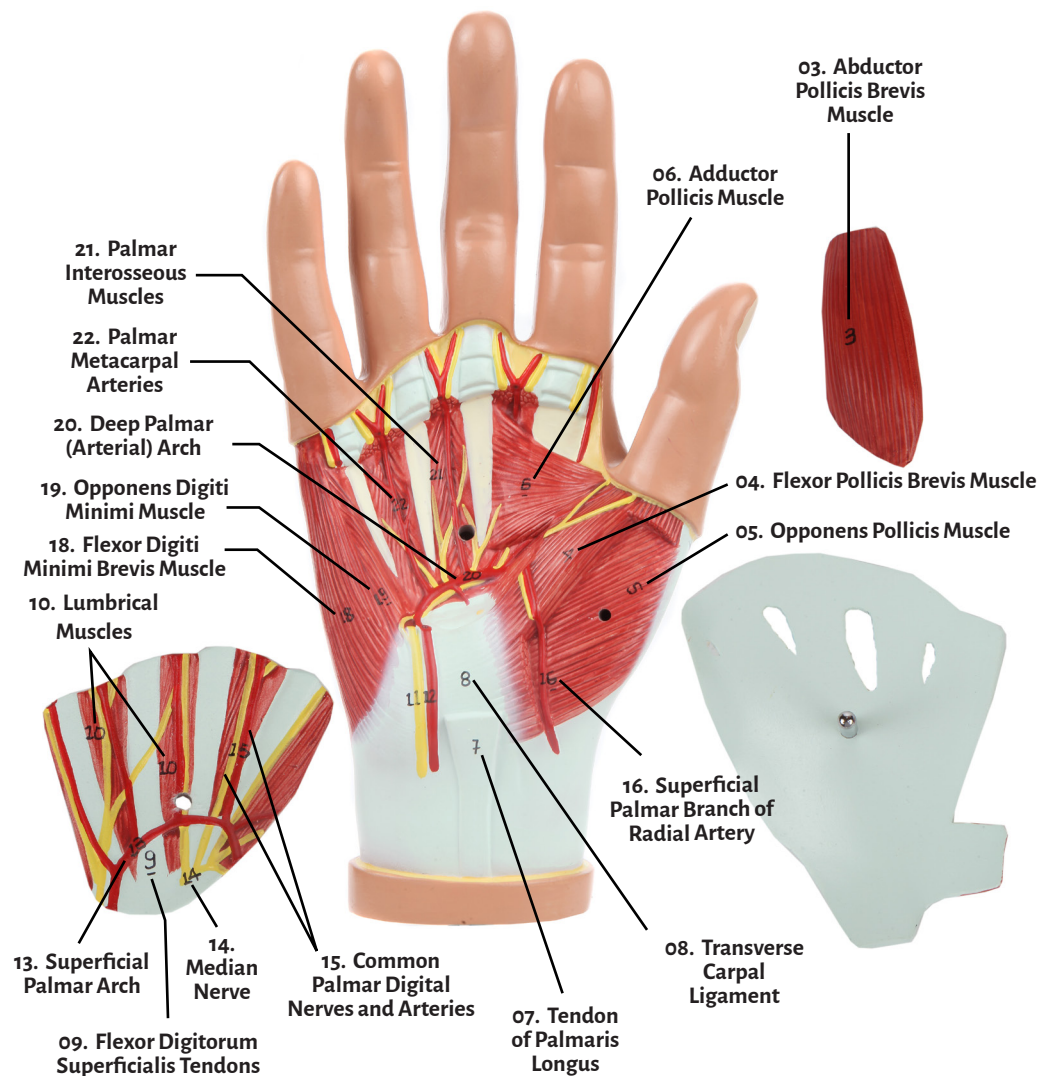
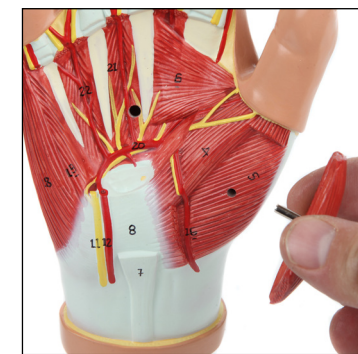
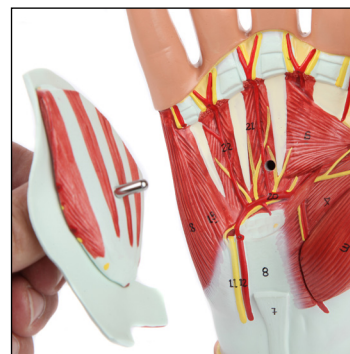
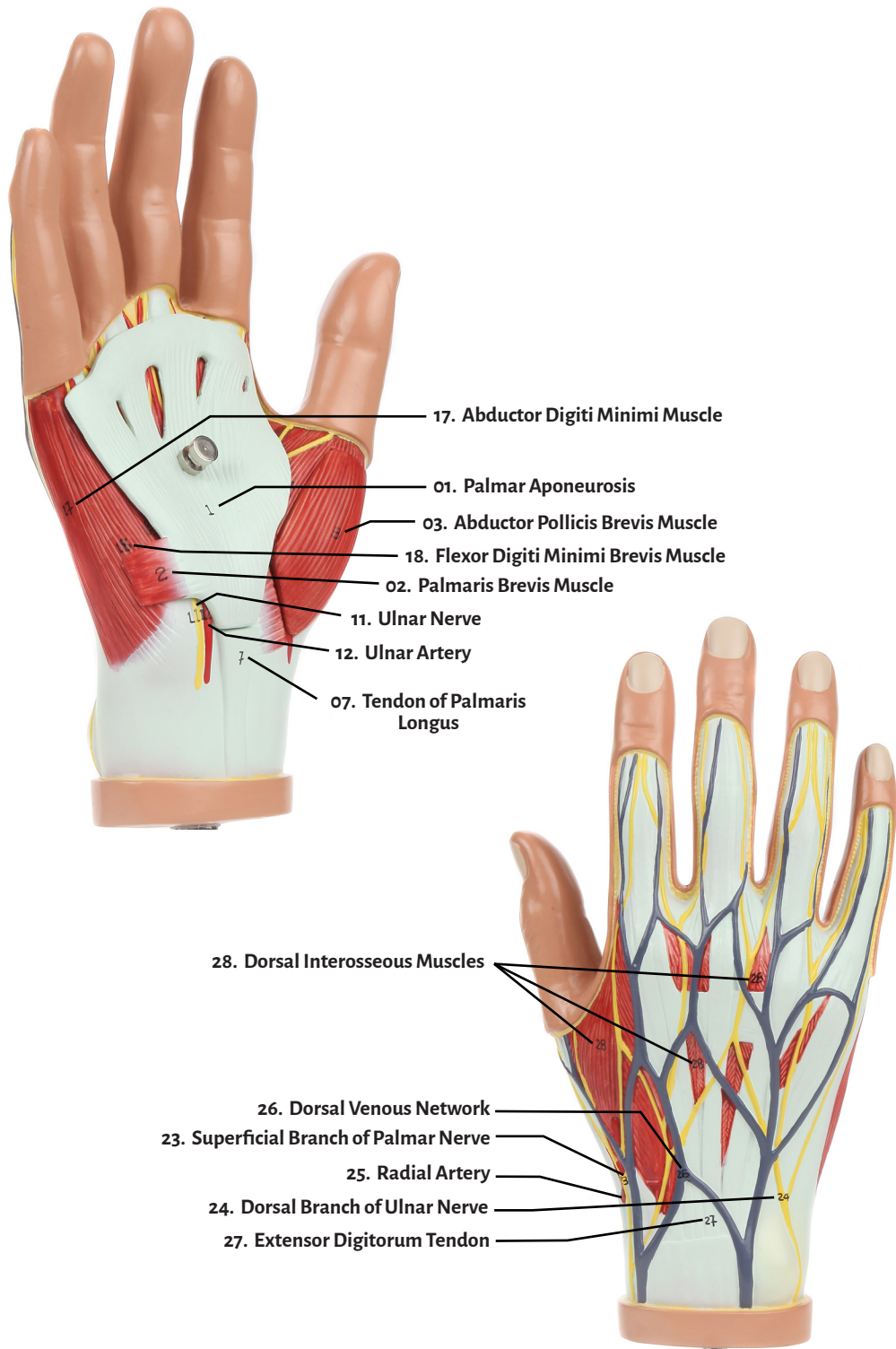




Axis Scientific Hand Model with Deep Layers

A-105873





- |  |  |
|--|--|
| 01. Palmar Aponeurosis                     | 15. Common Palmar Digital Nerves and Arteries  |
| 02. Palmaris Brevis Muscle                 | 16. Superficial Palmar Branch of Radial Artery |
| 03. Abductor Pollicis Brevis Muscle        | 17. Abductor Digiti Minimi Muscle              |
| 04. Flexor Pollicis Brevis Muscle          | 18. Flexor Digiti Minimi Brevis Muscle         |
| 05. Opponens Pollicis Muscle               | 19. Opponens Digiti Minimi Muscle              |
| 06. Adductor Pollicis Muscle               | 20. Deep Palmar (Arterial) Arch                |
| 07. Tendon of Palmaris Longus              | 21. Palmar Interosseous Muscles                |
| 08. Transverse Carpal Ligament             | 22. Palmar Metacarpal Arteries                 |
| 09. Flexor Digitorum Superficialis Tendons | 23. Superficial Branch of Palmar Nerve         |
| 10. Lumbrical Muscle                       | 24. Dorsal Branch of Ulnar Nerve               |
| 11. Ulnar Nerve                            | 25. Radial Artery                              |
| 12. Ulnar Artery                           | 26. Dorsal Venous Network of Hand              |
| 13. Superficial Palmar Arch                | 27. Extensor Digitorum Tendon                  |
| 14. Median Nerve                           | 28. Dorsal Interosseous Muscles                |

