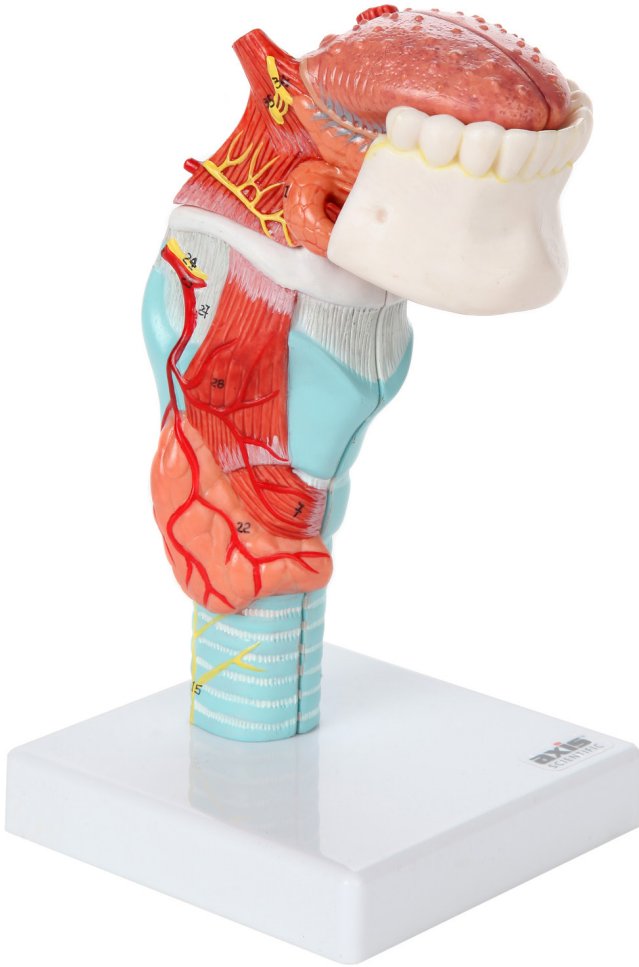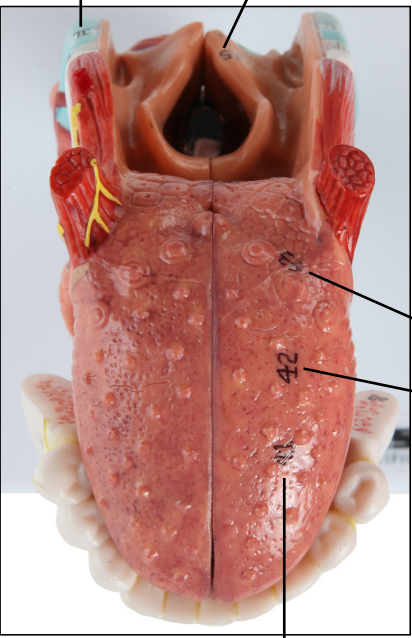




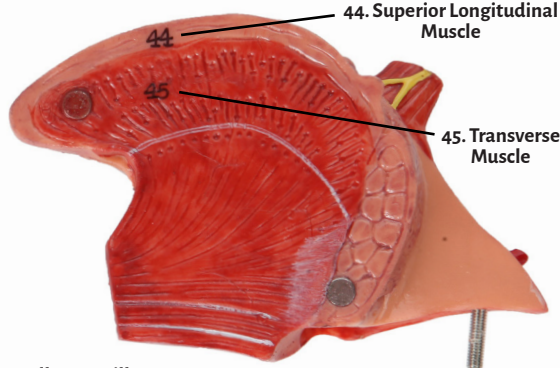
Axis Scientific Larynx & Tongue

A-106119

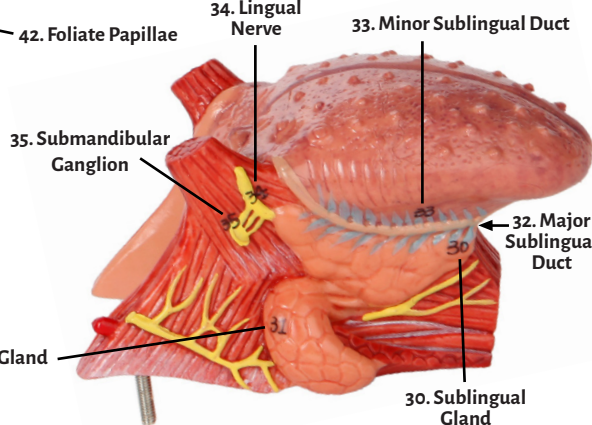
11. Triticeal Cartilage 15. Aryepiglottic Fold



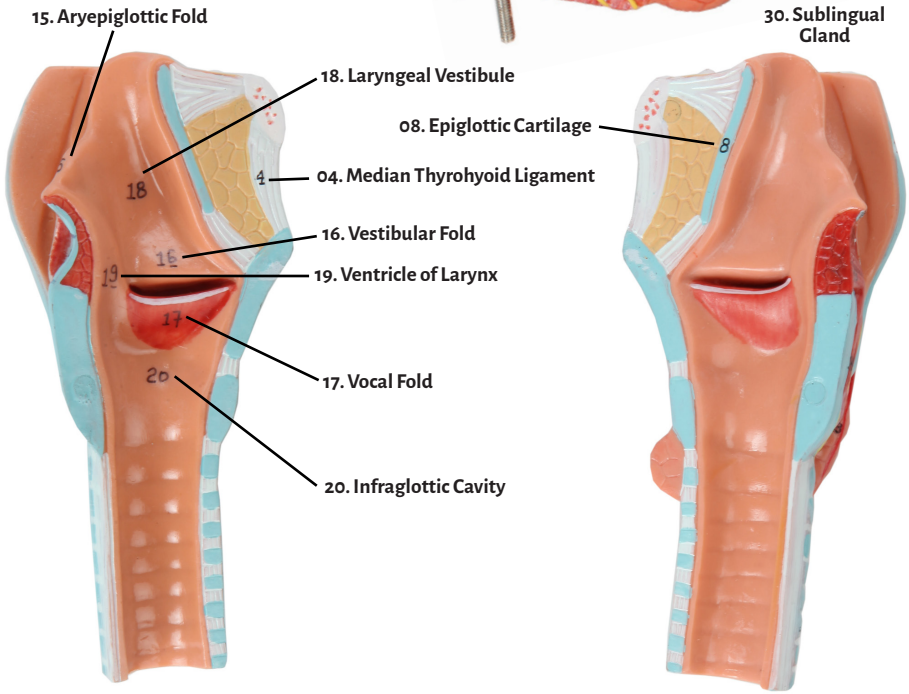
41. Dorsum of Tongue



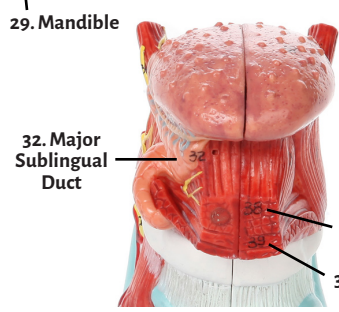
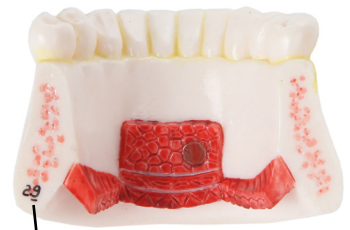44. Superior Longitudinal Muscle
45. Transverse Muscle



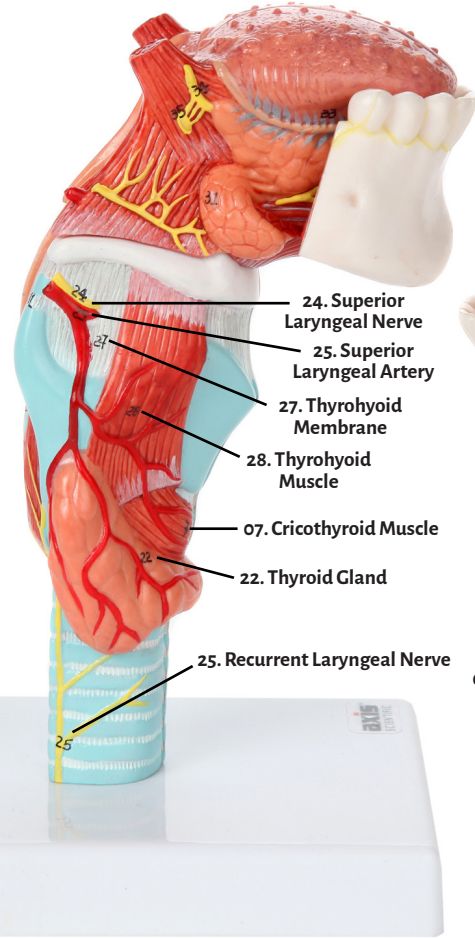
34. Lingual Nerve 33. Minor Sublingual Duct
32. Major Sublingual Duct
35. Submandibular Ganglion
31. Submandibular Gland
30. Sublingual Gland



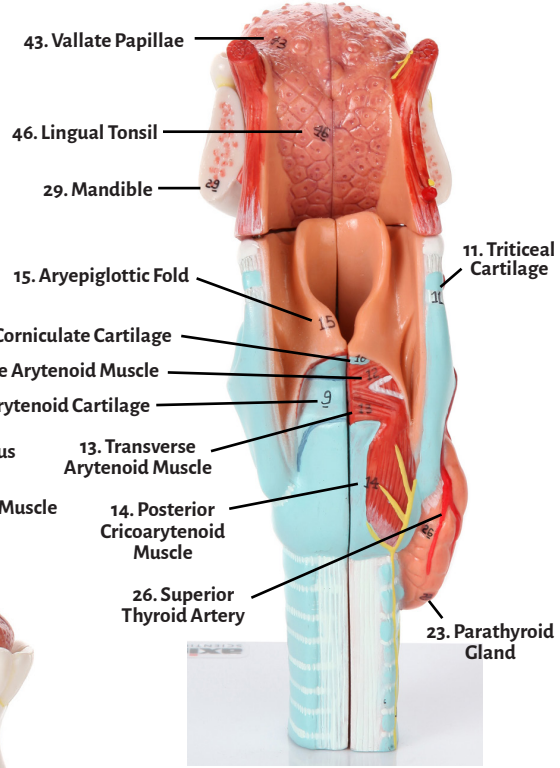
15. Aryepiglottic Fold
18. Laryngeal Vestibule
08. Epiglottic Cartilage
04. Median Thyrohyoid Ligament
16. Vestibular Fold
19. Ventricle of Larynx
17. Vocal Fold
20. Infraglottic Cavity



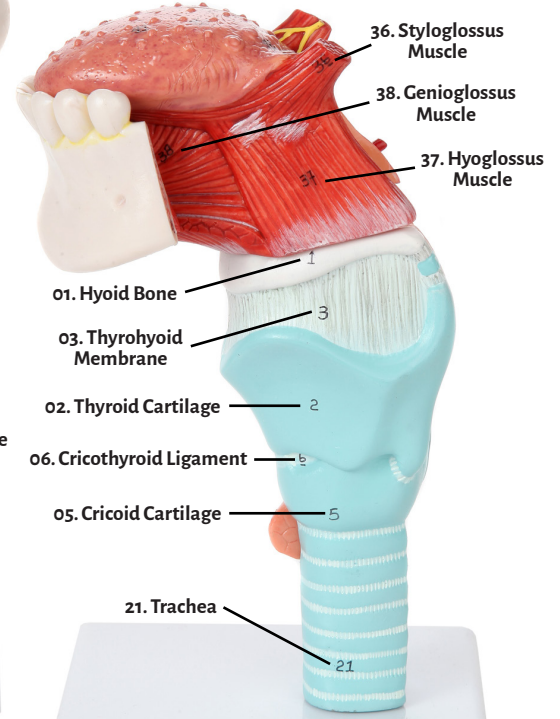
29. Mandible
32. Major Sublingual Duct
38. Genioglossus Muscle
39. Geniohyoid Muscle



24. Superior Laryngeal Nerve
25. Superior Laryngeal Artery
27. Thyrohyoid Membrane
28. Thyrohyoid Muscle
07. Cricothyroid Muscle
22. Thyroid Gland
25. Recurrent Laryngeal Nerve



43. Vallate Papillae
46. Lingual Tonsil
29. Mandible
15. Aryepiglottic Fold
11. Triticeal Cartilage
10. Corniculate Cartilage
12. Oblique Arytenoid Muscle
09. Arytenoid Cartilage
13. Transverse Arytenoid Muscle
14. Posterior Cricoaarytenoid Muscle
26. Superior Thyroid Artery
23. Parathyroid Gland



36. Styloglossus Muscle
38. Genioglossus Muscle
37. Hyoglossus Muscle
01. Hyoid Bone
03. Thyrohyoid Membrane
02. Thyroid Cartilage
06. Cricothyroid Ligament
05. Cricoid Cartilage
21. Trachea



01. Hyoid Bone
02. Thyroid Cartilage
03. Thyrohyoid Membrane
04. Median Thyrohyoid Ligament
05. Cricoid Cartilage
06. Cricothyroid Ligament
07. Cricothyroid Muscle
08. Epiglottic Cartilage
09. Arytenoid Cartilage
10. Corniculate Cartilage
11. Triticeal Cartilage
12. Oblique Arytenoid Muscle
13. Transverse Arytenoid Muscle
14. Posterior Cricoarytenoid Muscle
15. Aryepiglottic Fold
16. Vestibular Fold
17. Vocal Fold
18. Laryngeal Vestibule
19. Ventricle of Larynx
20. Infraglottic Cavity
21. Trachea
22. Thyroid Gland
23. Parathyroid Gland
24. Superior Laryngeal Nerve
25. Recurrent Laryngeal Nerve
26. Superior Thyroid Artery
27. Thyrohyoid Membrane
28. Thyrohyoid Muscle
29. Mandible
30. Sublingual Gland
31. Submandibular Gland
32. Major Sublingual Duct
33. Minor Sublingual Duct
34. Lingual Nerve
35. Submandibular Ganglion
36. Styloglossus Muscle
37. Hyoglossus Muscle
38. Genioglossus Muscle
39. Geniohyoid Muscle
40. Mylohyoid Muscle
41. Dorsum of Tongue
42. Foliate Papillae
43. Vallate Papillae
44. Superior Longitudinal Muscle
45. Transverse Muscle
46. Lingual Tonsil
47. Epiglottic Vallecula

