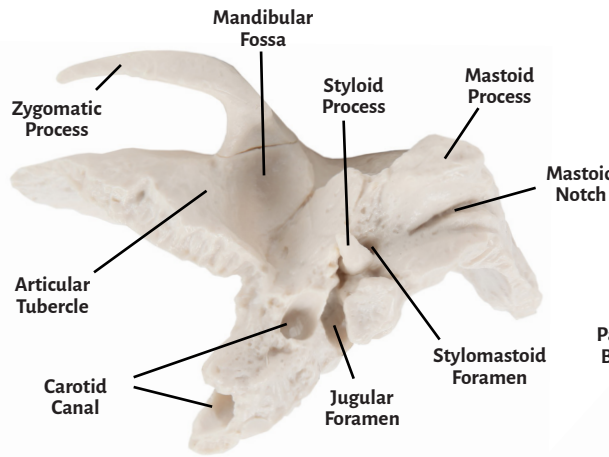
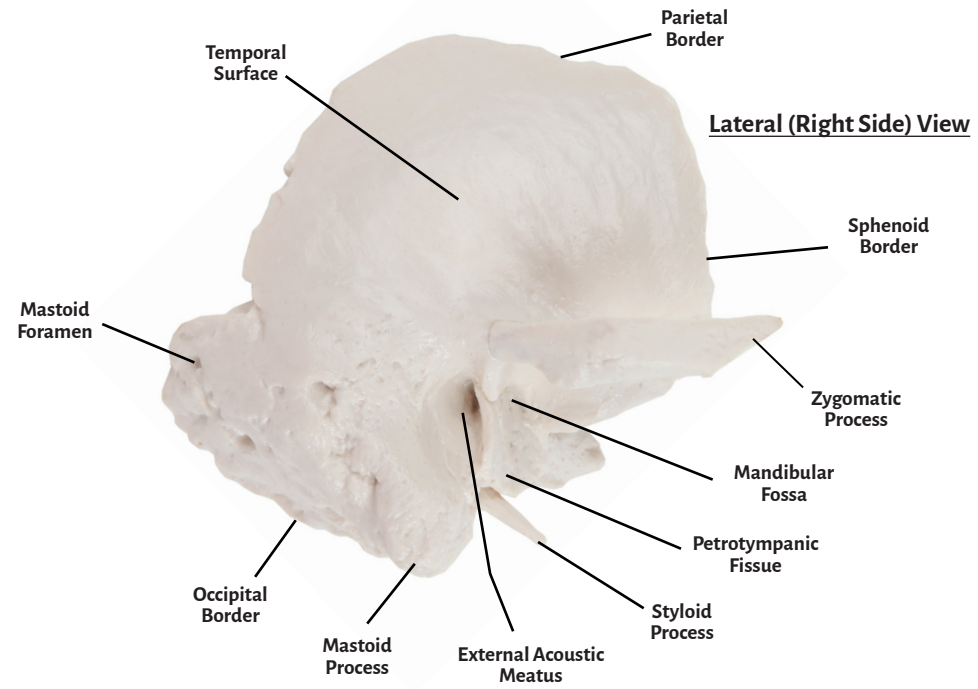
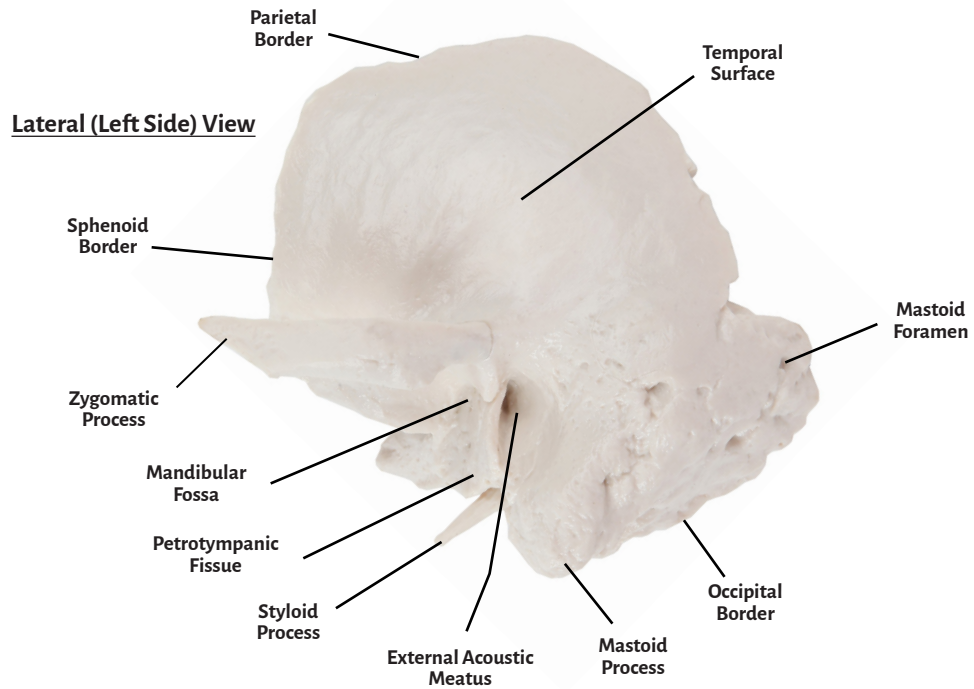


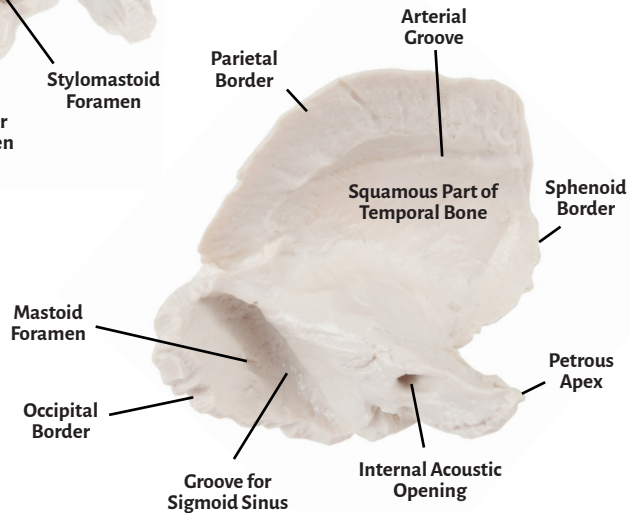


Axis Scientific Temporal Bone (Left & Right)

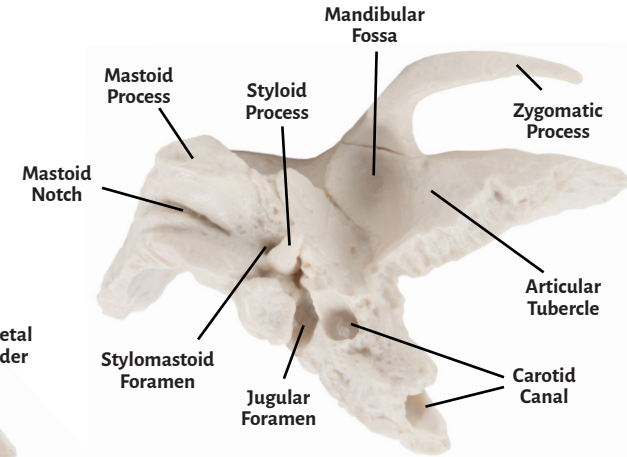
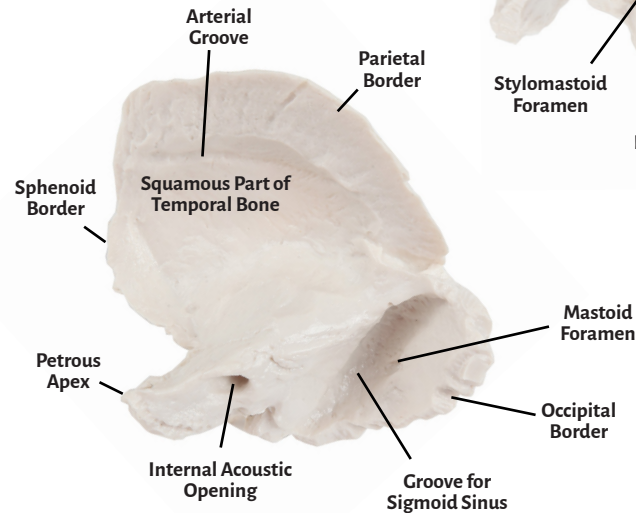
A-106189 & A-106190



Medial (Internal) View



Medial (Internal) View



Inferior View



Articular Tubercle

Mandibular Fossa

Sphenoid Border

Mastoid Foramen

Parietal Border

Zygomatic Process

Occipital Border

Mandibular Fossa

Mastoid Notch

Styloid Process

Arterial Groove

Petrotympenic Fissure

Temporal Surface

Mastoid Process

Carotid Canal

External Acoustic Meatus

Petrous Apex

Jugular Foramen

Stylomastoid Foramen

**Squamous Part of
Temporal Bone**

**Internal Acoustic
Opening**

**Groove for
Sigmoid Sinus**

