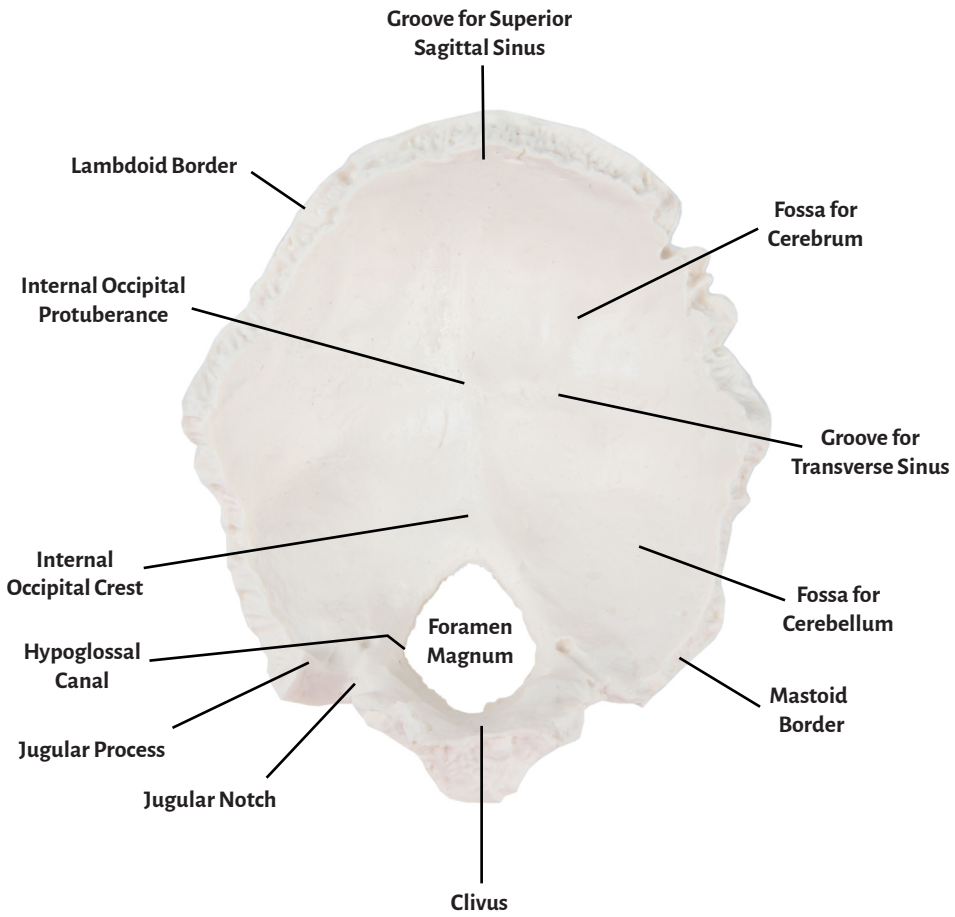


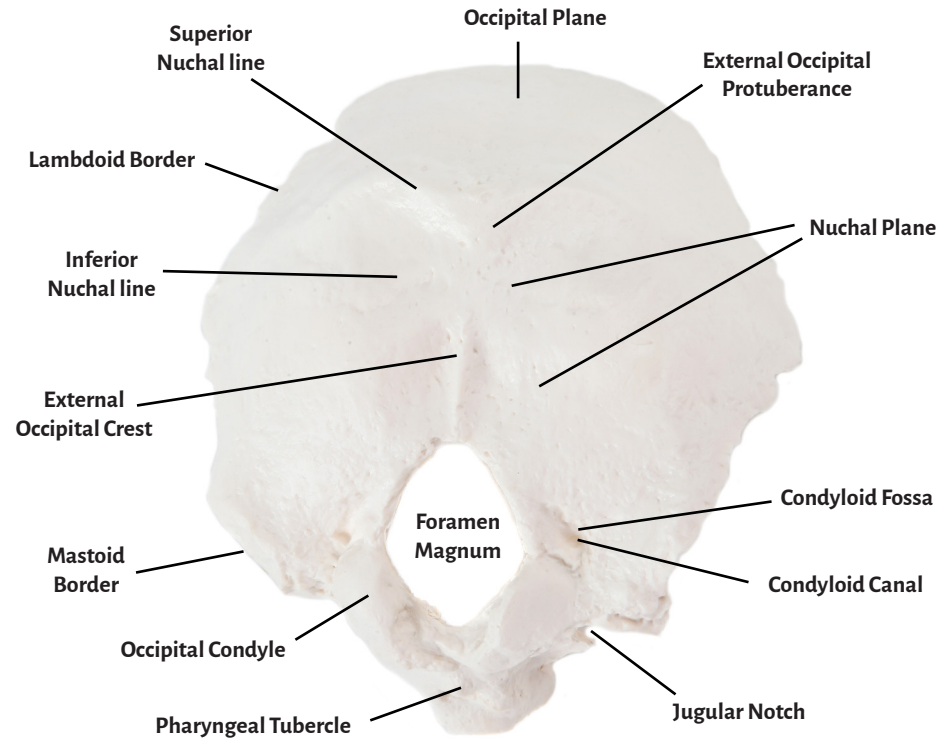


**Axis Scientific Occipital Bone**

**A-106191**



Superior View



Inferior View



<b>Clivus</b>	<b>Fossa for Cerebrum</b>	<b>Occipital Condyle</b>
<b>Lambdoid Border</b>	<b>Groove for Transverse Sinus</b>	<b>External Occipital Crest</b>
<b>Internal Occipital Protuberance</b>	<b>Fossa for Cerebellum</b>	<b>Condylod Fossa</b>
<b>Internal Occipital Crest</b>	<b>Mastoid Border</b>	<b>Condylod Canal</b>
<b>Jugular Process</b>	<b>Superior Nuchal line</b>	<b>Pharyngeal Tubercle</b>
<b>Hypoglossal Canal</b>	<b>Inferior Nuchal line</b>	<b>Nuchal Plane</b>
<b>Jugular Notch</b>	<b>Occipital Plane</b>	<b>Foramen Magnum</b>
<b>Groove for Superior Sagittal Sinus</b>	<b>External Occipital Protuberance</b>	

