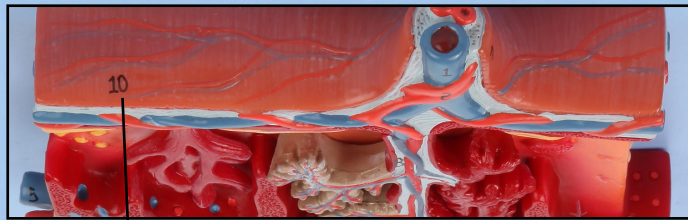




Axis Scientific Cross-Section of Placenta

A-106197




Amnion

Umbilical Vein

Umbilical Cord

Umbilical Artery

Chorionic Plate



Intervillous Space

Chorionic Villus

Fetal Arteriole & Venule

Uterine Vein

Basal Plate

Uterine Artery

Myometrium

Placental Septum

Endometrial Vein

Spiral Artery



1. Umbilical Vein

9. Fetal Arteriole & Venule

2. Umbilical Artery

10. Amnion

3. Myometrium

11. Chorionic Plate

4. Maternal Artery

12. Basal Plate

5. Maternal Vein

13. Intervillous Space

6. Placental Septum

14. Endometrial Artery

7. Umbilical Cord

15. Endometrial Vein

8. Chorionic Villus

