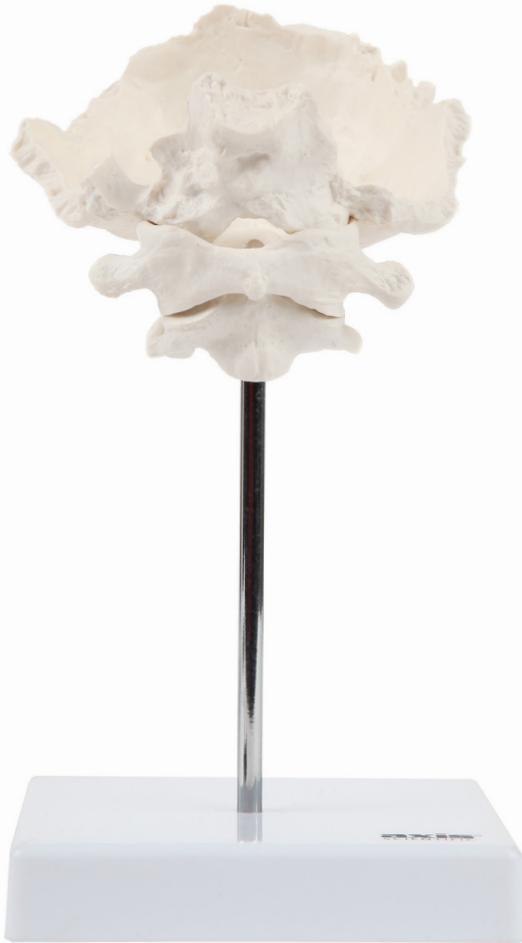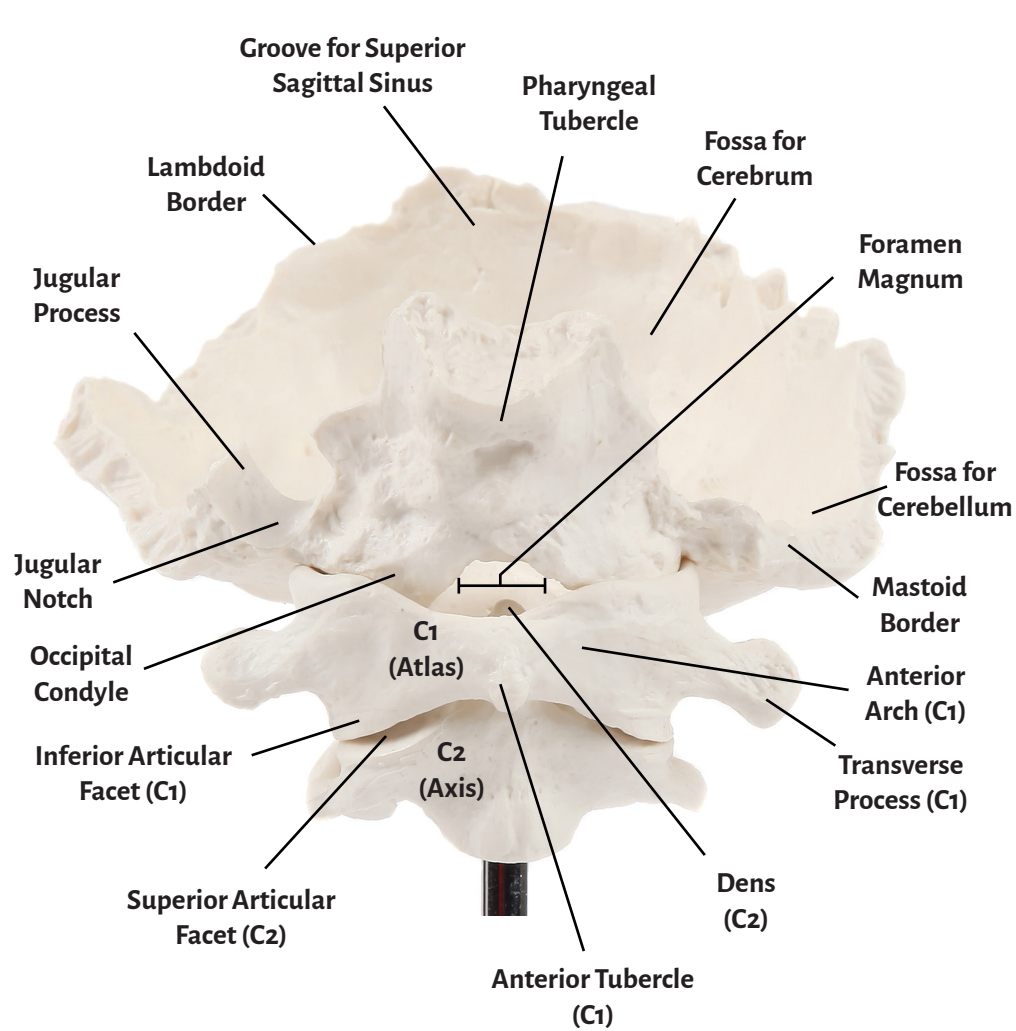


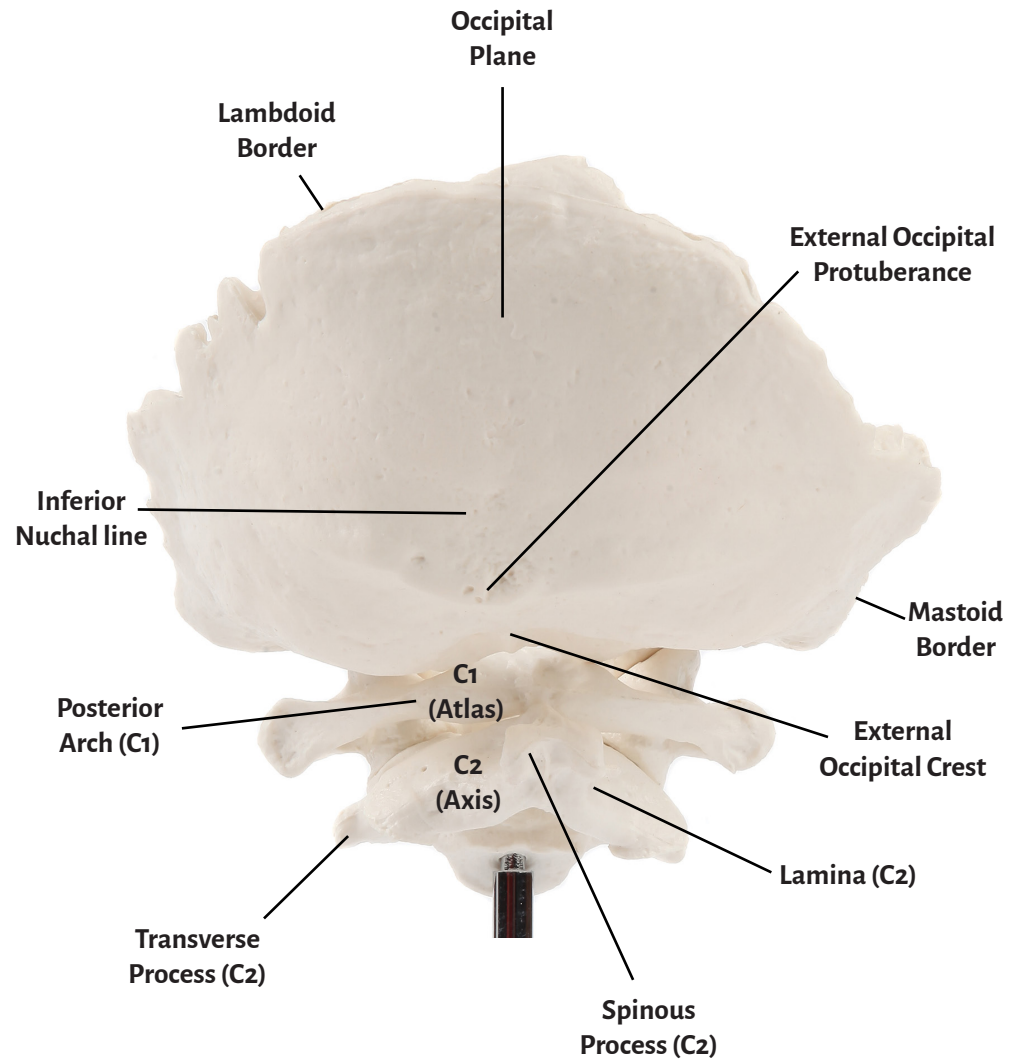


Axis Scientific Occipital Bone & Cervical Spine (C1 & C2)

A-106199



Anterior View



Posterior View



C1 (Atlas)	Groove for Superior Sagittal Sinus
C2 (Axis)	Lambdoid Border
Inferior Articular Facet (C1)	Occipital Condyle
Anterior Tubercle (C1)	Inferior Nuchal line
Anterior Arch (C1)	Foramen Magnum
Posterior Arch (C1)	Jugular Notch
Transverse Process (C1)	Jugular Process
Spinous Process (C2)	Mastoid Border
Superior Articular Facet (C2)	External Occipital Protuberance
Dens (C2)	External Occipital Crest
Lamina (C2)	Pharyngeal Tubercle
Transverse Process (C2)	Lambdoid Border
Fossa for Cerebrum	Occipital Plane
Fossa for Cerebellum	

