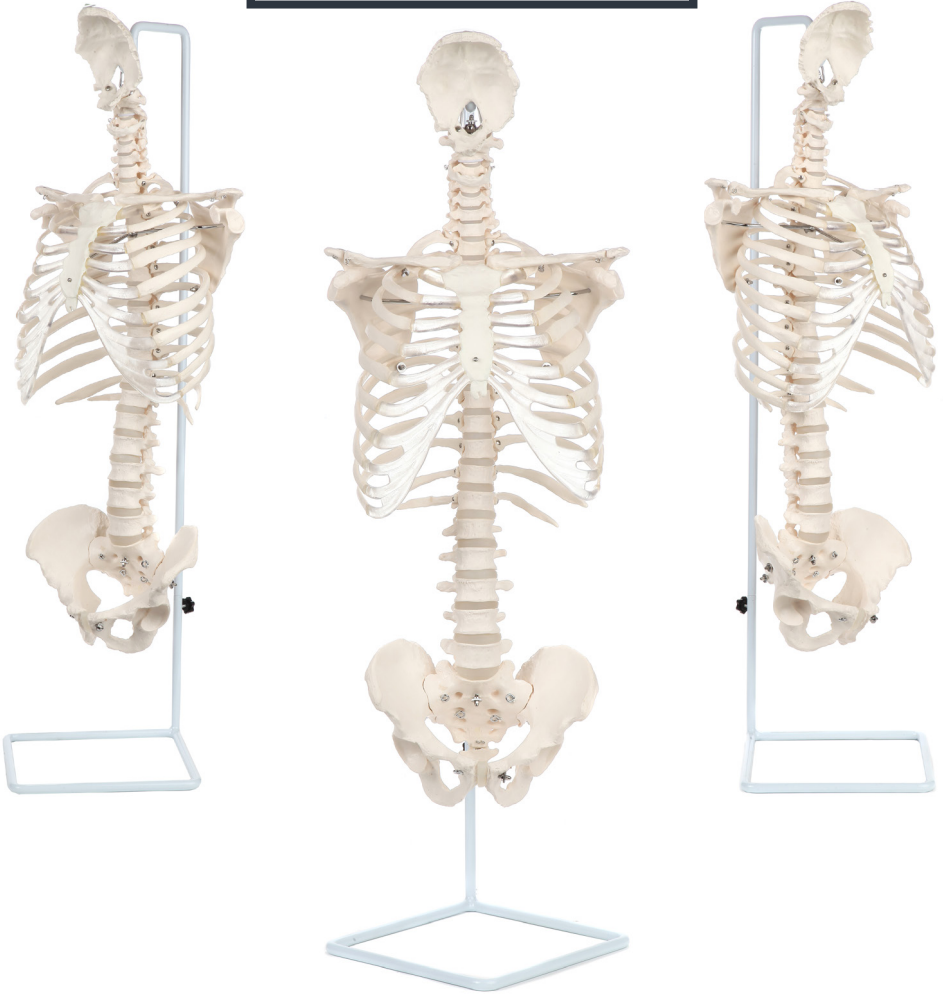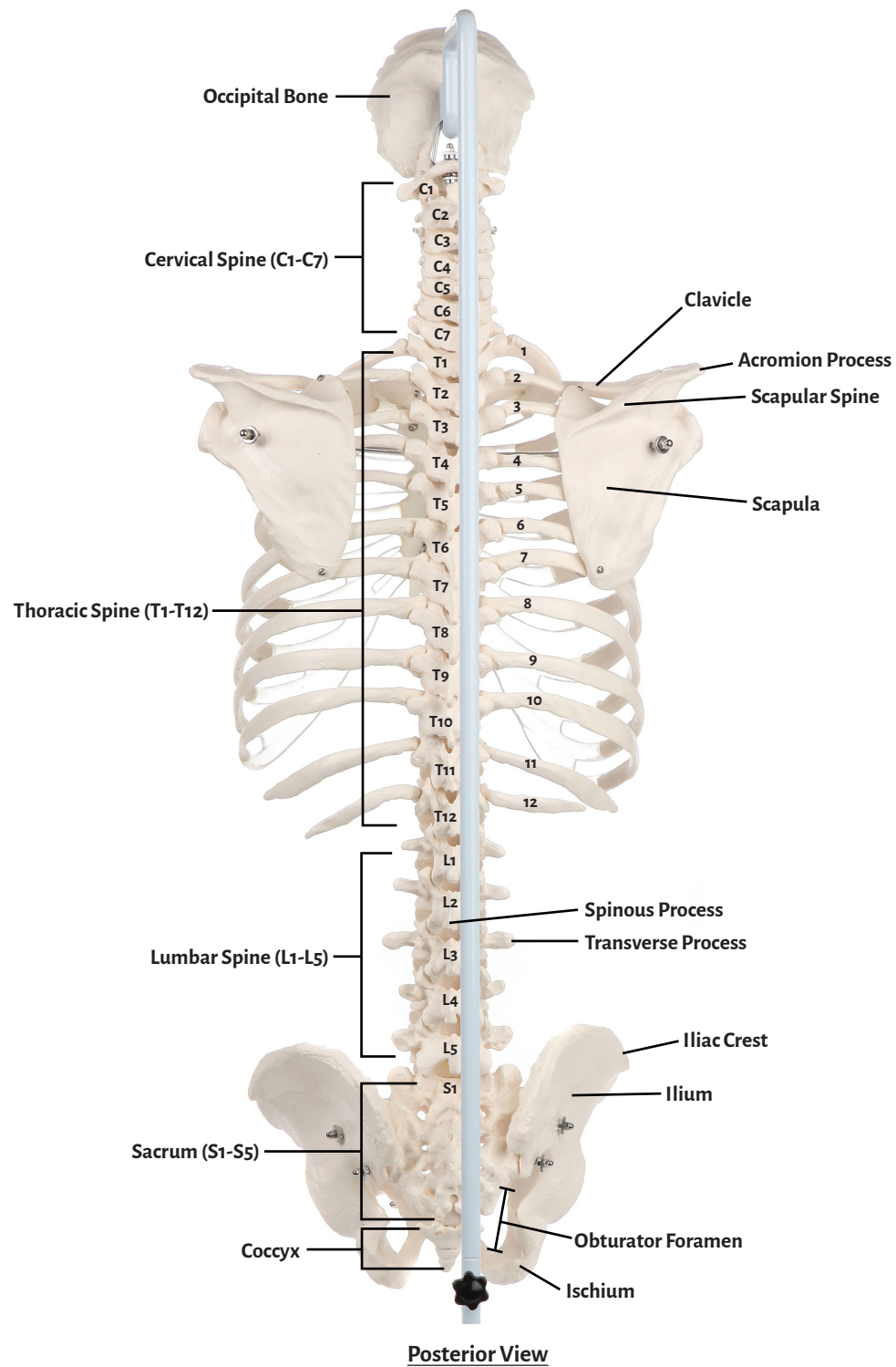
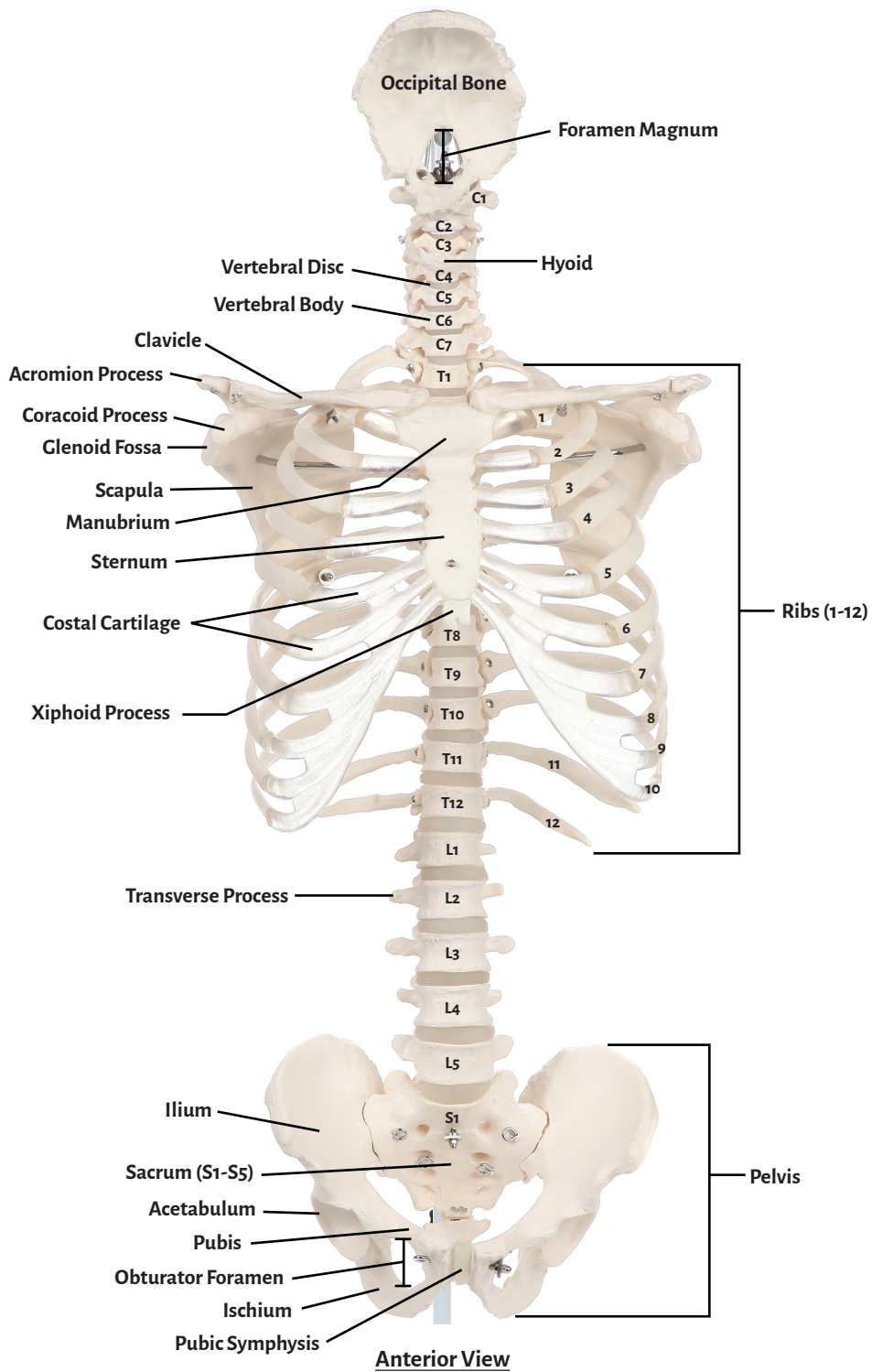




**Axis Scientific Vertebral Column with Rib Cage**

**A-106200**





**Occipital Bone**

**Pelvis**

**Lumbar Spine (L1-L5)**

**Foramen Magnum**

**Acetabulum**

**Sacrum (S1-S5)**

**Hyoid**

**Ilium**

**Coccyx**

**Clavicle**

**Ischium**

**Vertebral Disc**

**Scapula**

**Pubis**

**Vertebral Body**

**Coracoid Process**

**Pubic Symphysis**

**Transverse Process**

**Acromion Process**

**Obturator Foramen**

**Spinous Process**

**Glenoid Fossa**

**Iliac Crest**

**Scapular Spine**

**Costal Cartilage**

**Sternum**

**Ribs (1-12)**

**Manubrium**

**Cervical Spine (C1-C7)**

**Xiphoid Process**

**Thoracic Spine (T1-T12)**

