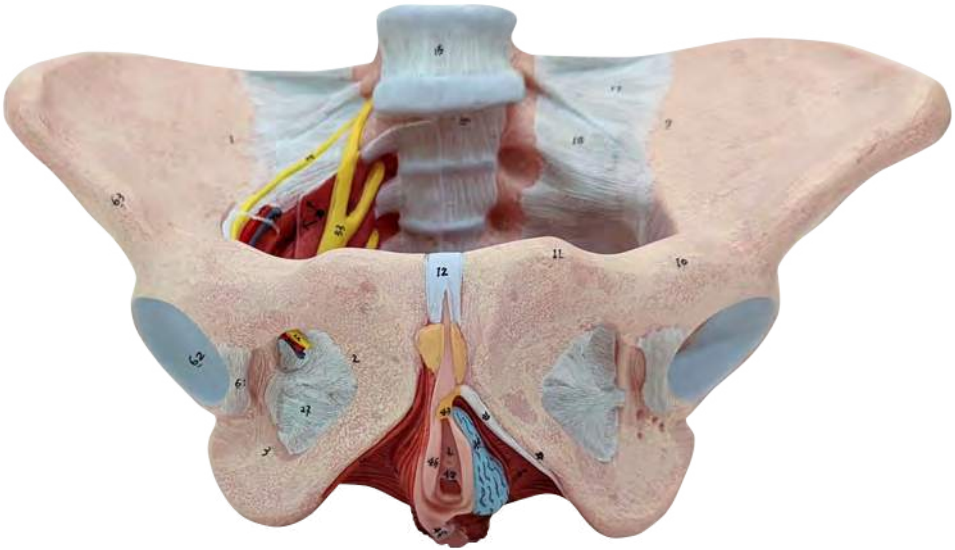
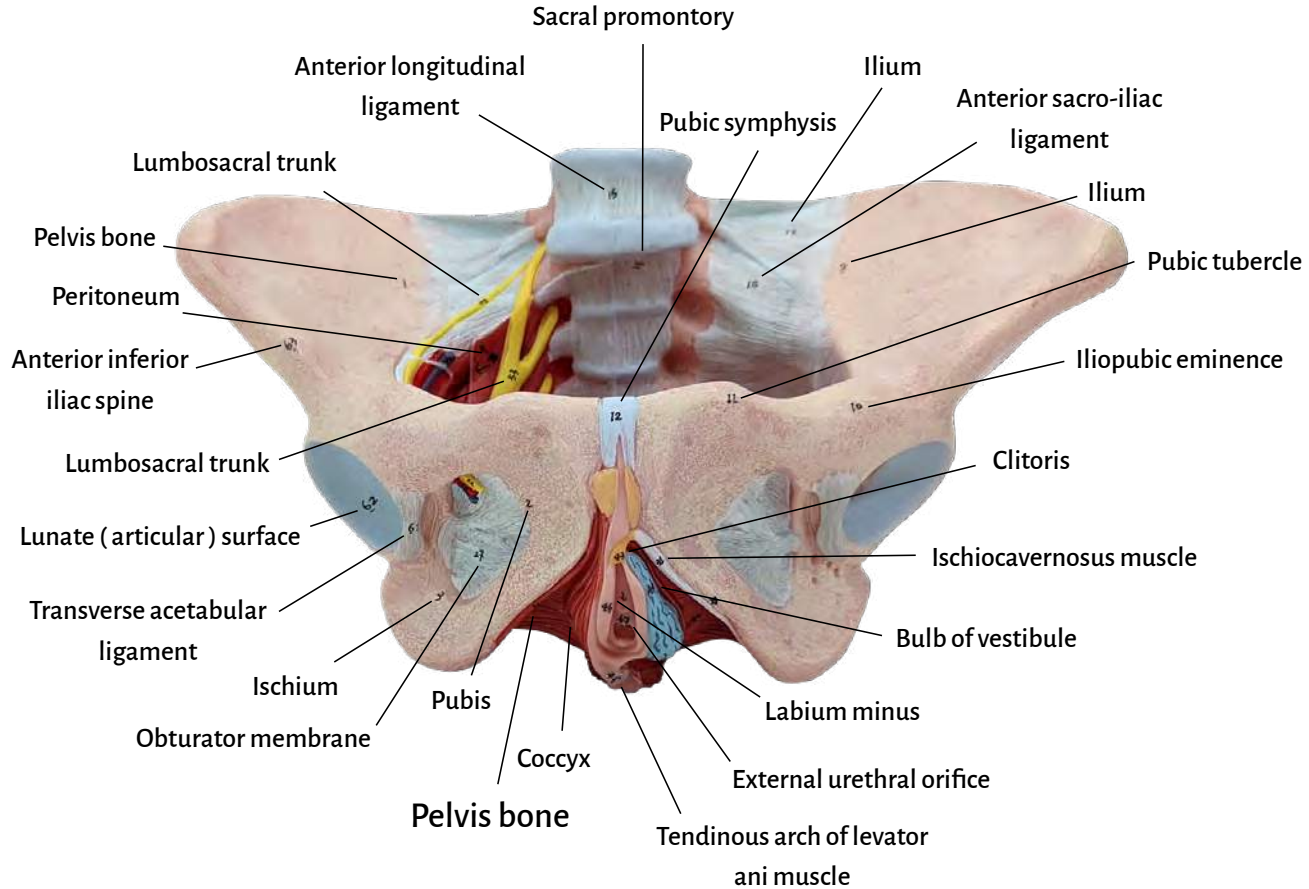


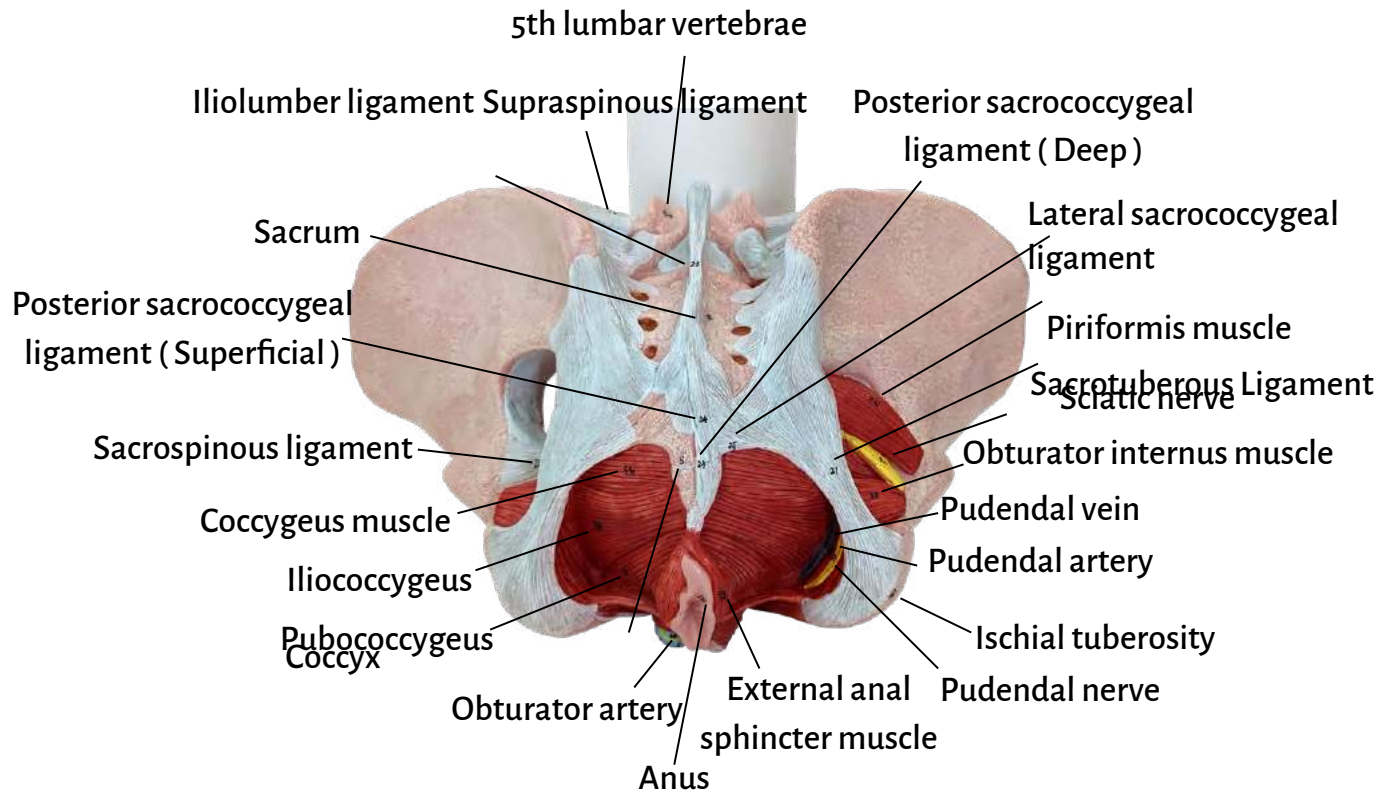
axis™
SCIENTIFIC

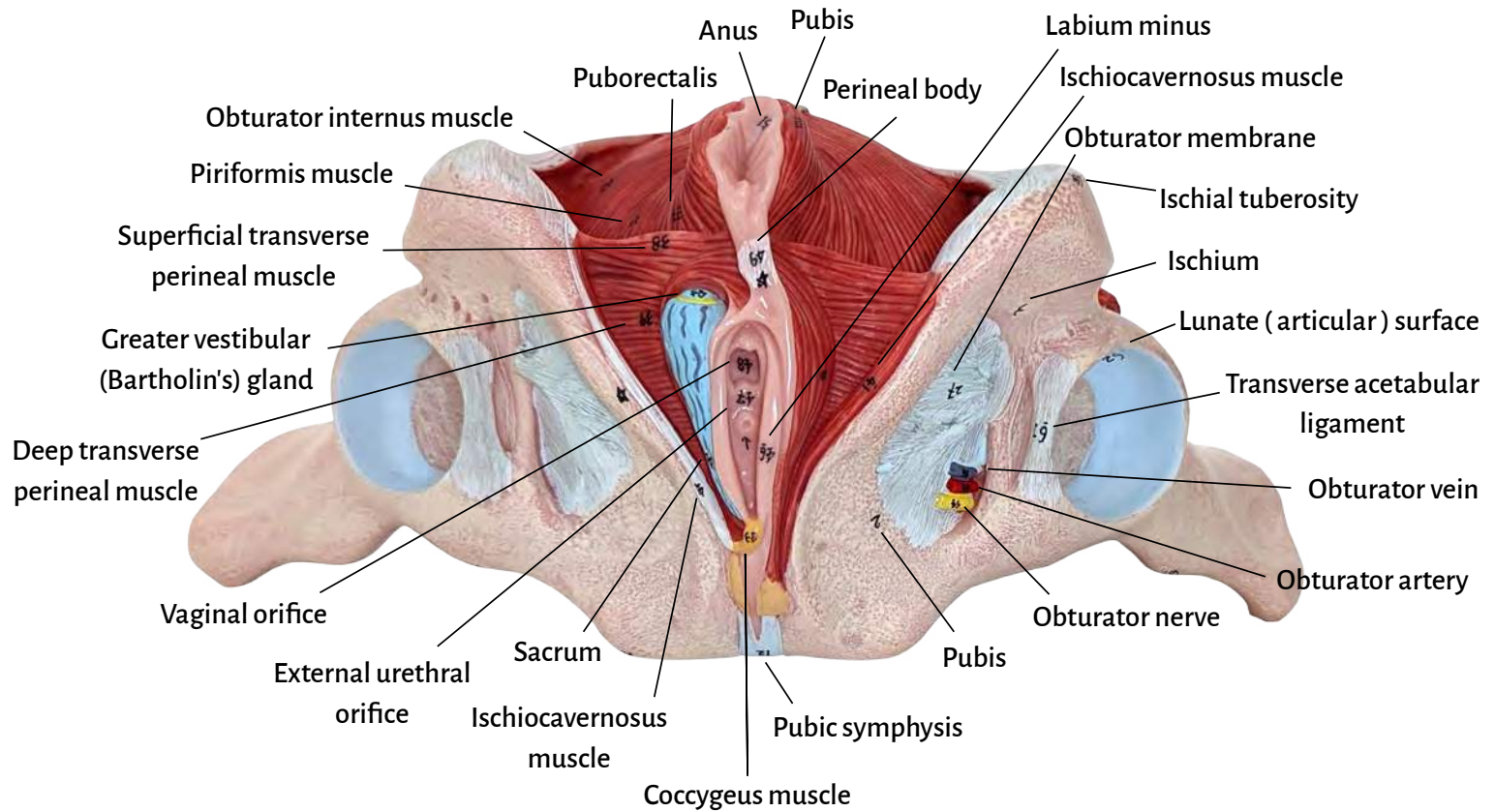


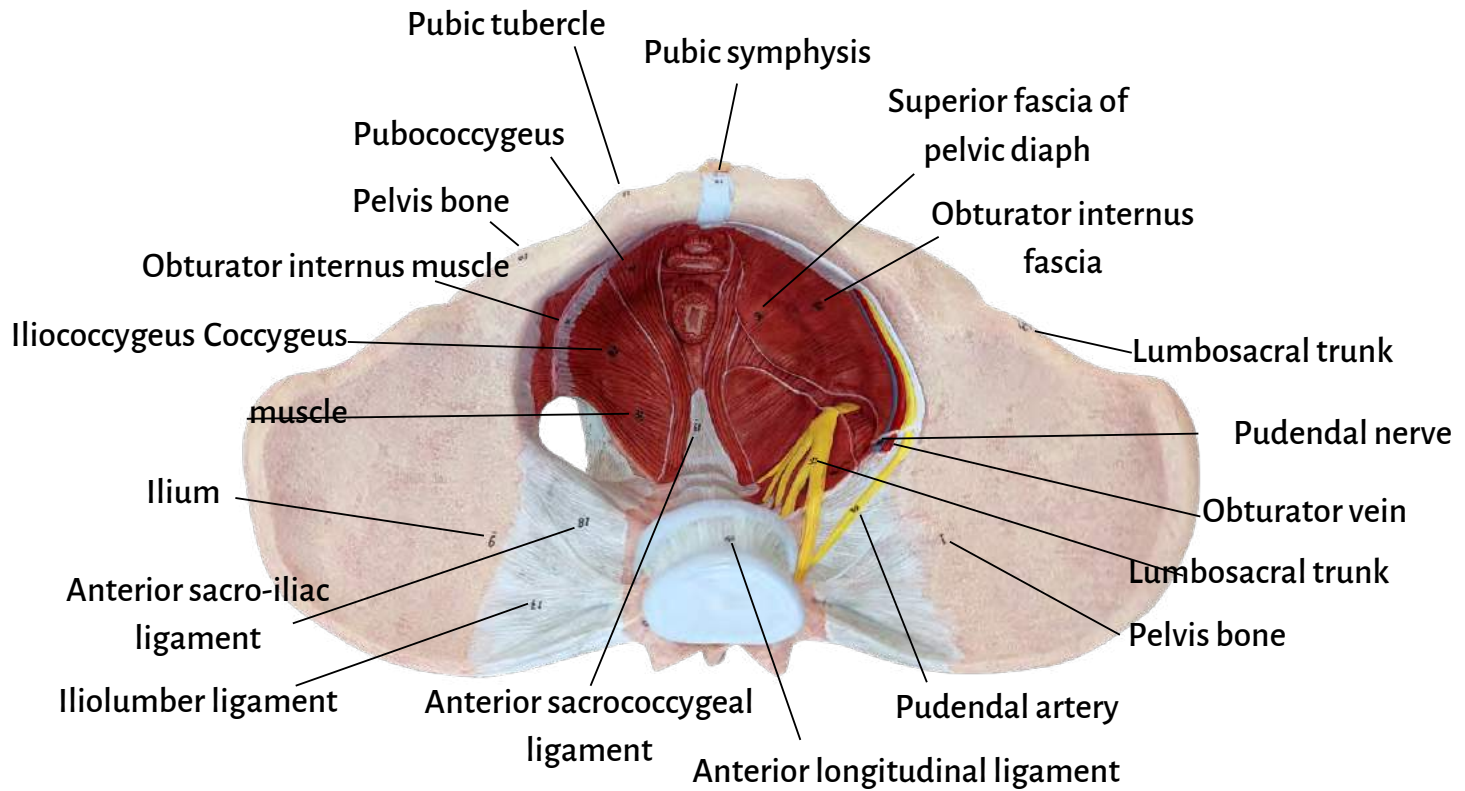
**Axis Scientific Female Pelvic Floor with Muscles,
Ligaments, and Nerves Anatomy Model**

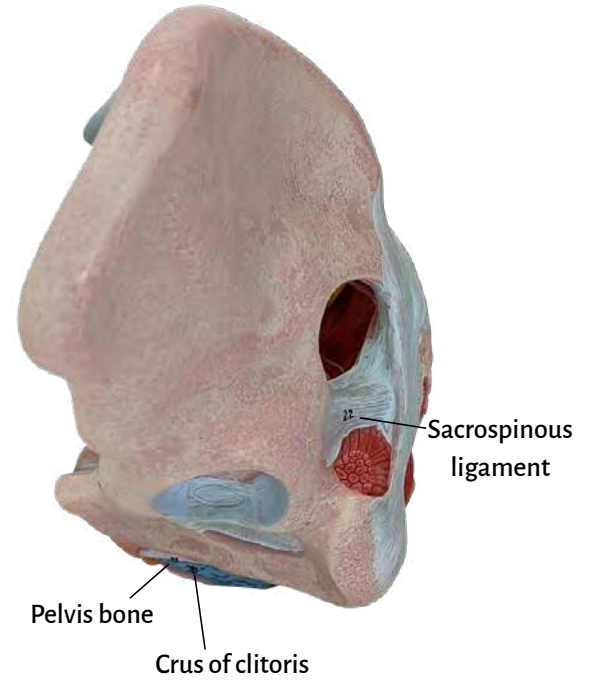
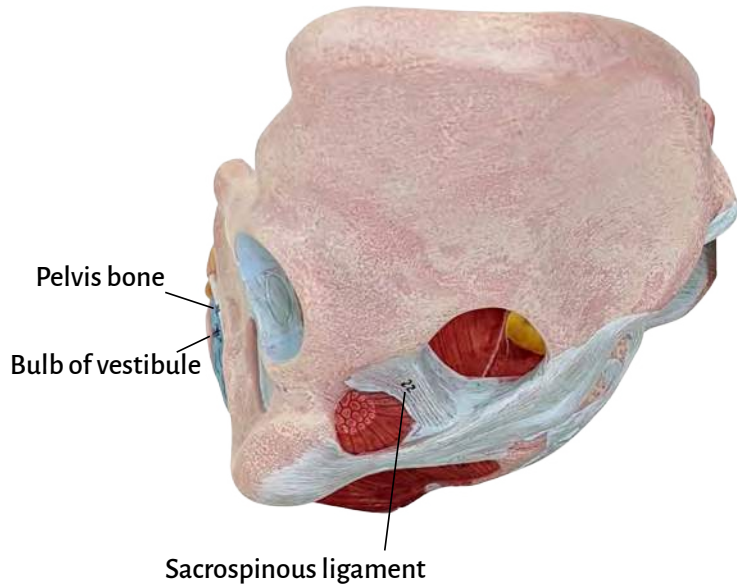
A-108852













| | |
|---|--|
| Pelvis bone | Coccygeus muscle |
| Pubis | Tendinous arch of levator ani muscle |
| Ischium | Obturator internus muscle |
| Sacrum | Piriformis muscle |
| Coccyx | Puborectalis |
| Anterior superior iliac spine | Superficial transverse perineal muscle |
| Iliac crest | Deep transverse perineal muscle |
| Transverse processes of lumbar vertebrae | Bullbospongiosus muscle |
| Ilium | Ischiocavernosus muscle |
| Iliopubic eminence | Crus of clitoris |
| Pubic tubercle | Clitoris |
| Pubic symphysis | Bulb of vestibule |
| Acetabulum | Greater vestibular (Bartholin's) gland |
| Ischial tuberosity | Labium minus |
| Anterior longitudinal ligament | External urethral orifice |
| Sacral promontory | Vaginal orifice |
| Iliolumbar ligament | Perineal body |
| Anterior sacro-iliac ligament | External anal sphincter muscle |
| Anterior sacrococcygeal ligament | Anus |
| Posterior sacroiliac ligament | Anococcygeal (ligament) body |
| Sacro-tuberous Ligament | Lumbosacral trunk |
| Sacrospinous ligament | Obturator nerve |
| Supraspinous ligament | Obturator artery |
| Posterior sacrococcygeal ligament (Superficial) | Obturator vein |
| Posterior sacrococcygeal ligament (Deep) | Pudendal nerve |
| Lateral sacrococcygeal ligament | Pudendal artery |
| Obturator membrane | Pudendal vein |
| Peritoneum | Sciatic nerve |
| Obturator internus fascia | Transverse acetabular ligament |
| Superior fascia of pelvic diaphragm | Lunate (articular) surface |
| Pubococcygeus | Anterior inferior iliac spine |
| Iliococcygeus | 5th lumbar vertebrae |

