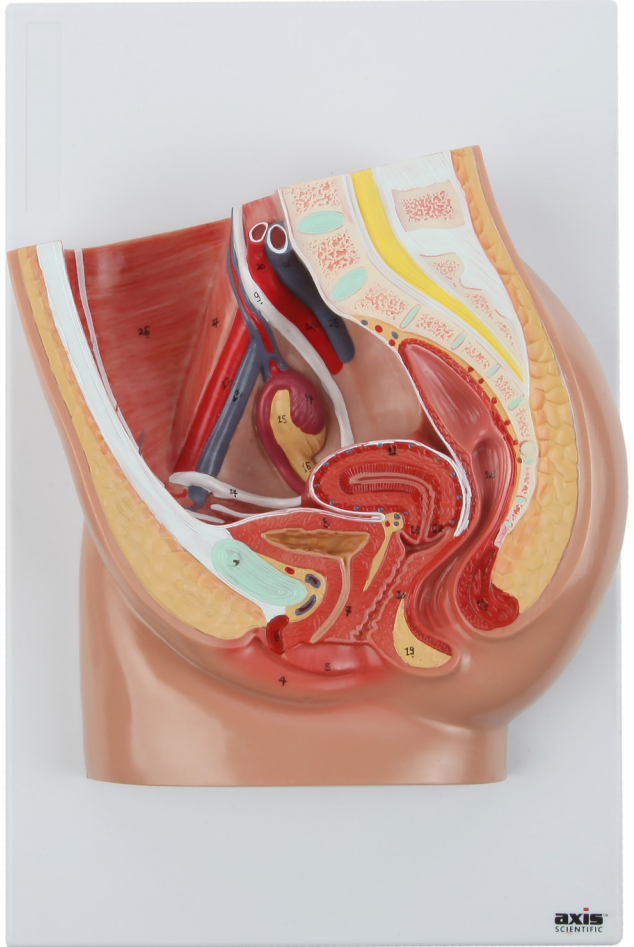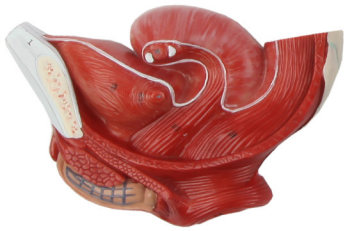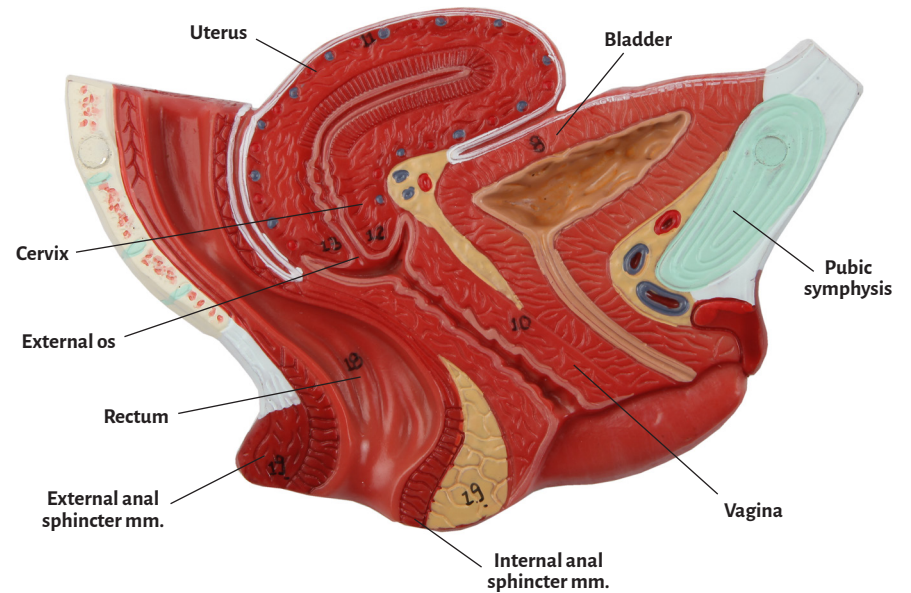
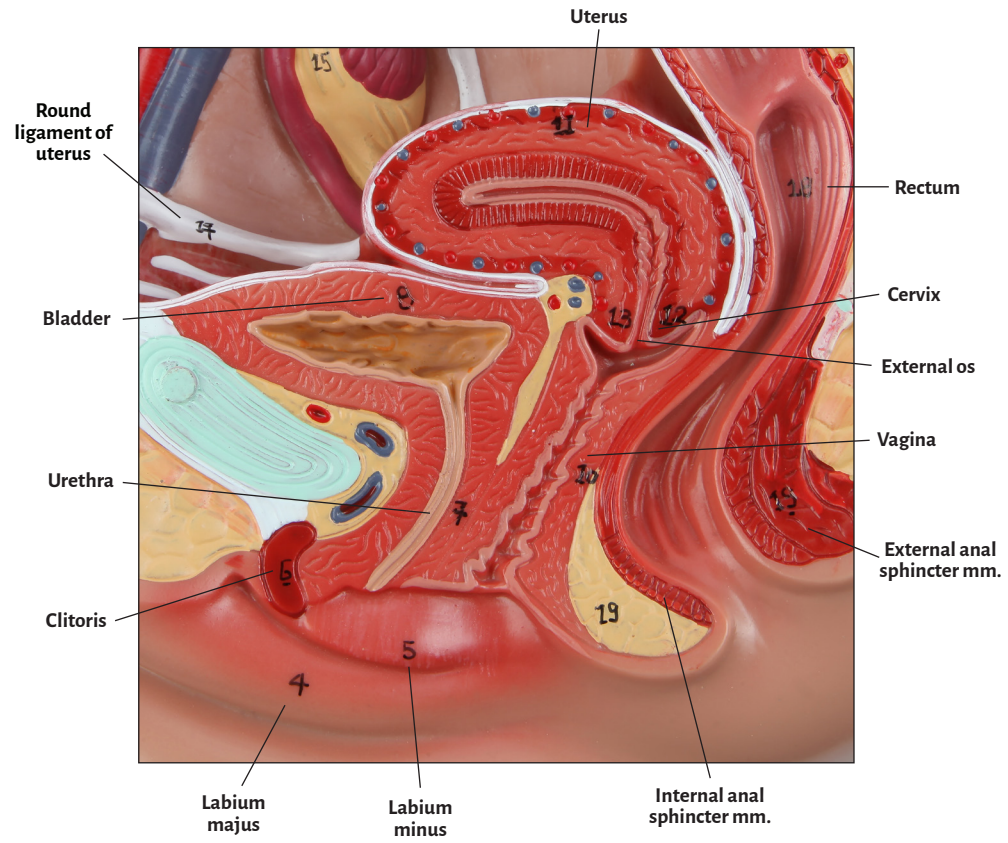
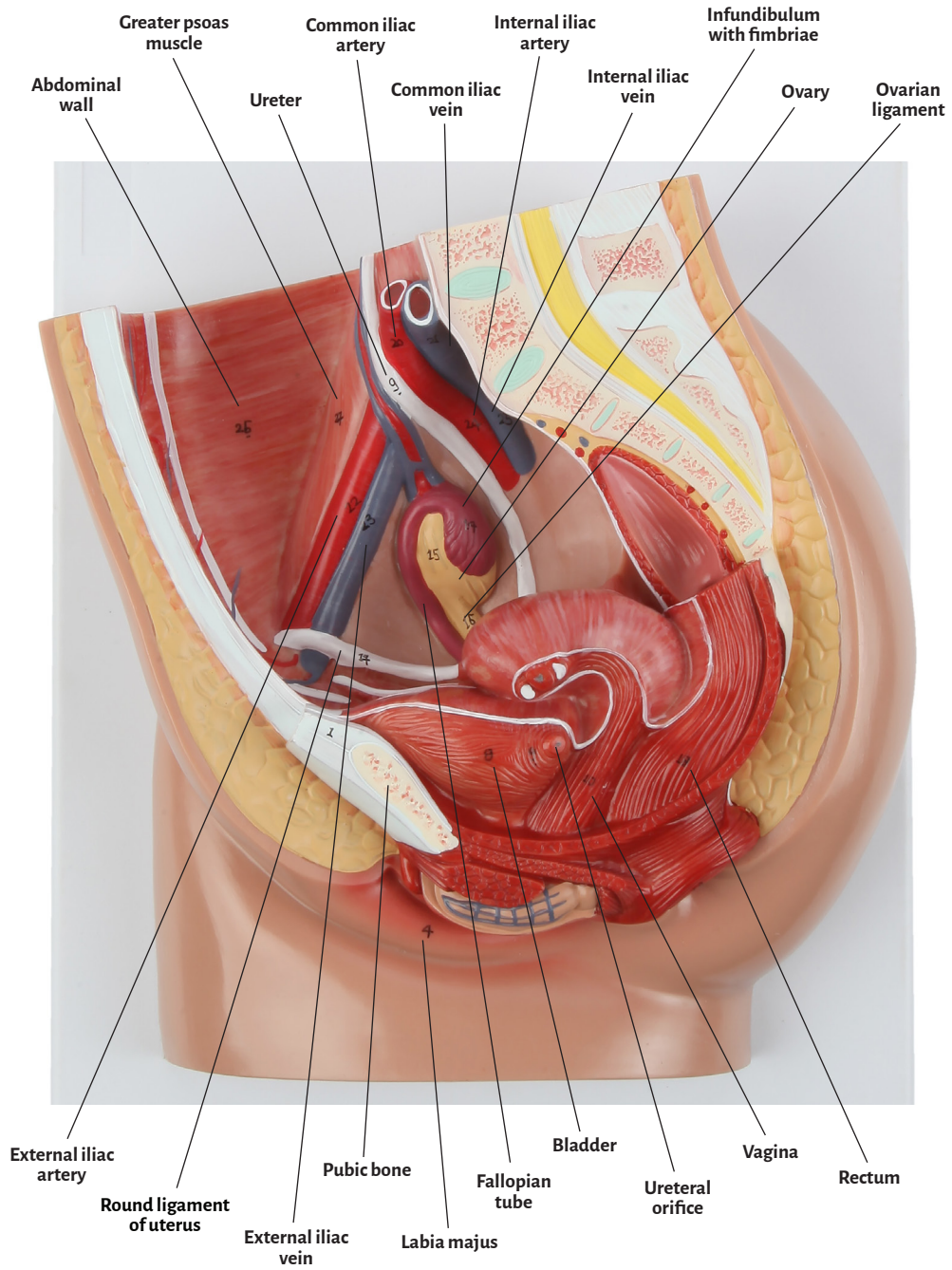


Axis Scientific Female Pelvis

A-109125





Abdominal wall	Internal anal sphincter muscle
Bladder	Labium majus
Cervix	Labium minus
Clitoris	Ovarian ligament
Common iliac artery	Ovary
Common iliac vein	Pubic symphysis
External anal sphincter muscle	Pubic bone
External os	Rectum
External iliac artery	Round ligament of uterus
External iliac vein	Ureteral orifice
Fallopian tube	Uterus
Greater psoas muscle	Ureter
Infundibulum with fimbriae	Urethra
Internal iliac artery	Vagina
Internal iliac vein	

