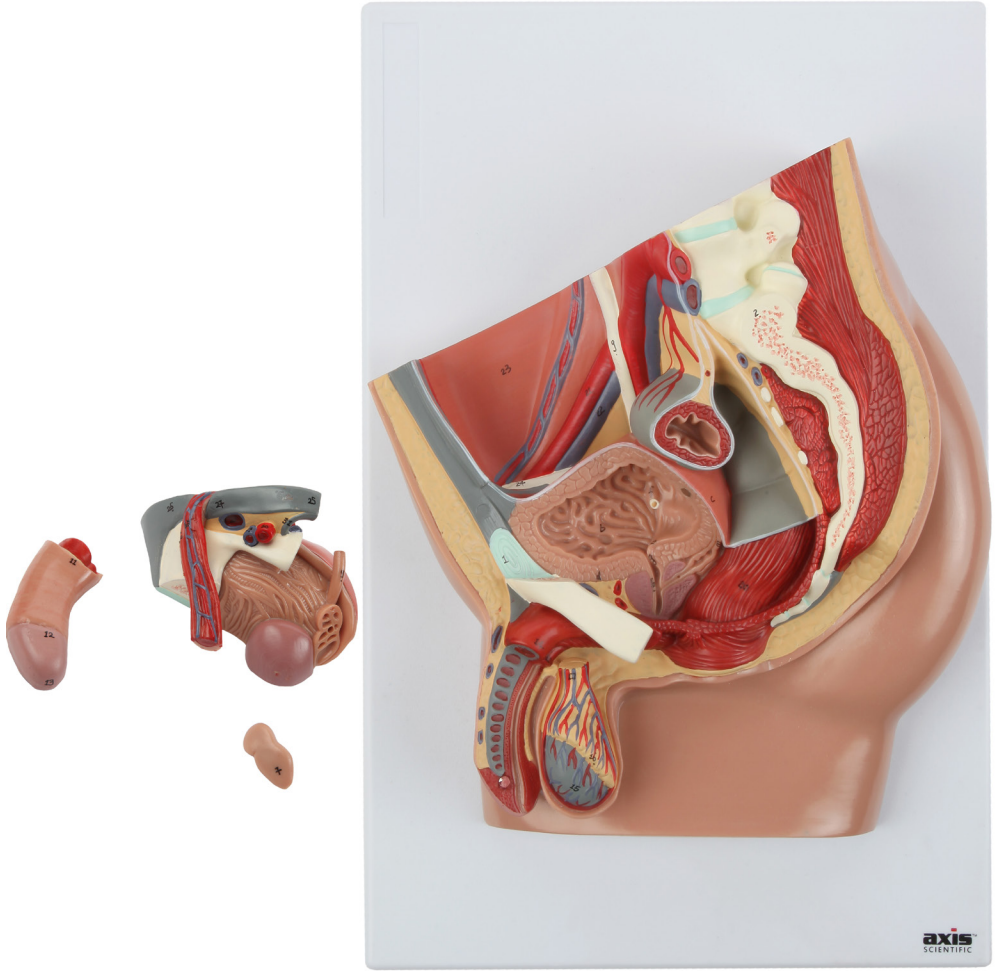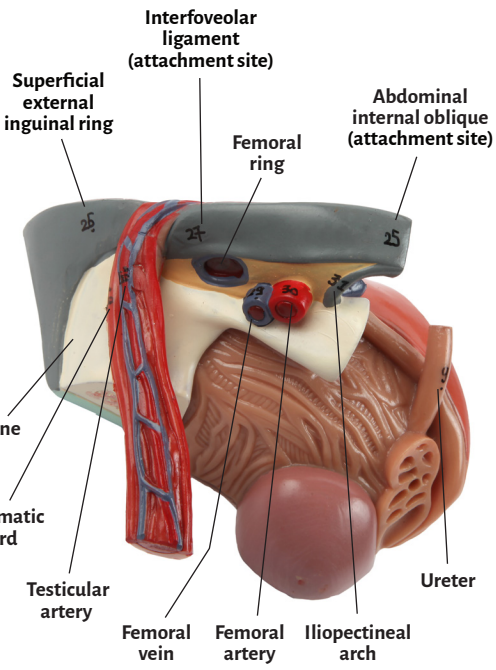
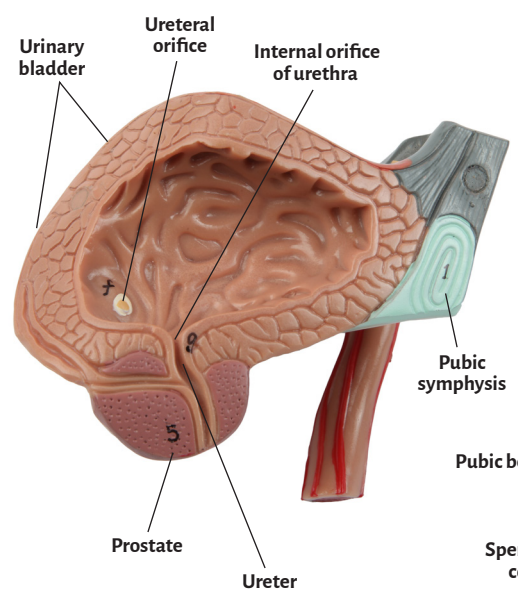
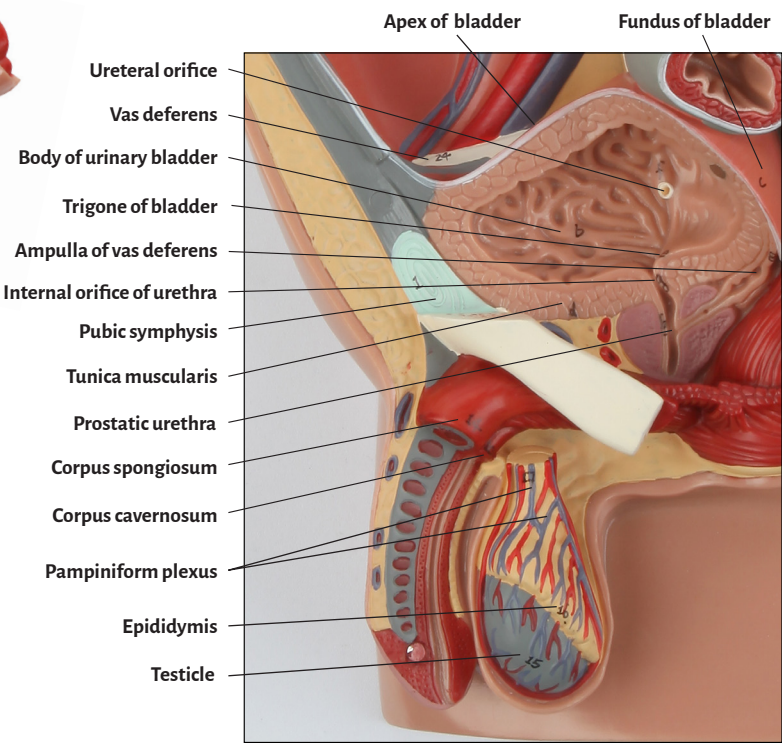
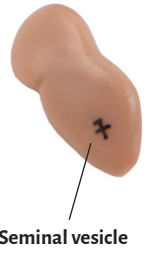
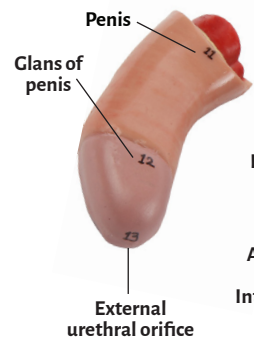
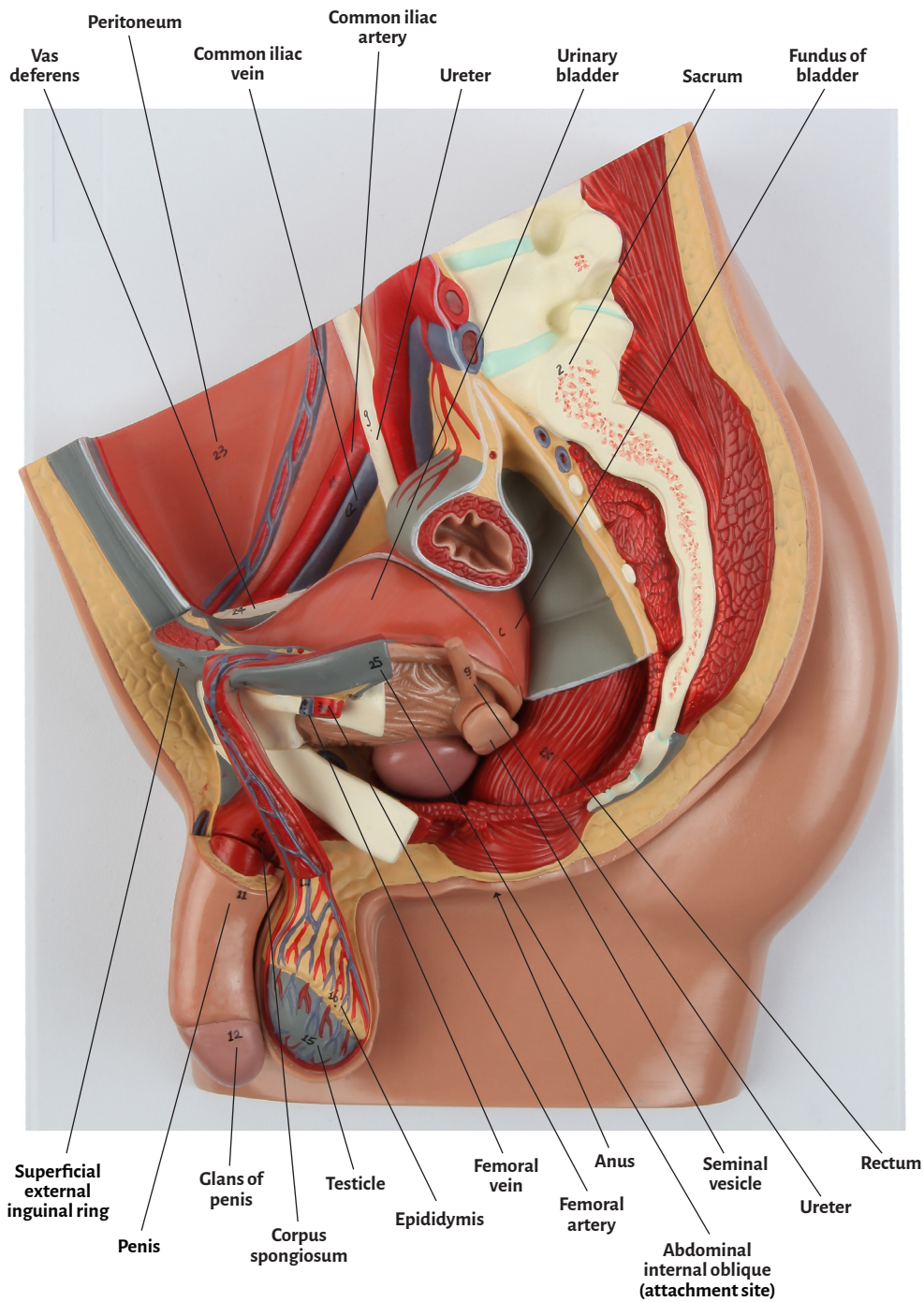


Axis Scientific Male Pelvis

A-109126





Abdominal internal oblique (attachment site)	Penis
Ampulla of vas deferens	Peritoneum
Anus	Prostate
Apex of bladder	Prostatic urethra
Body of urinary bladder	Pubic bone
Common iliac artery	Pubic symphysis
Common iliac vein	Rectum
Corpus cavernosum	Sacrum
Corpus spongiosum	Seminal vesicle
Epididymis	Spermatic cord
External urethral orifice	Superficial external inguinal ring
Femoral artery	Testicle
Femoral ring	Testicular artery
Femoral vein	Trigone of bladder
Fundus of bladder	Tunica muscularis
Glans of penis	Ureter
Iliopectineal arch	Ureteral orifice
Interfoveolar ligament (attachment site)	Urinary bladder
Internal orifice of urethra	Vas deferens
Pampiniform plexus	

