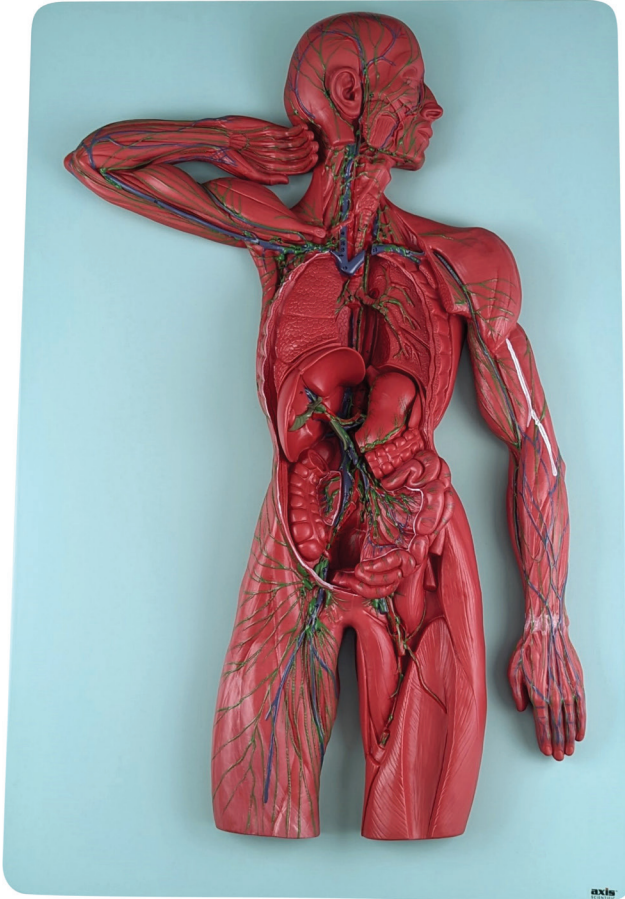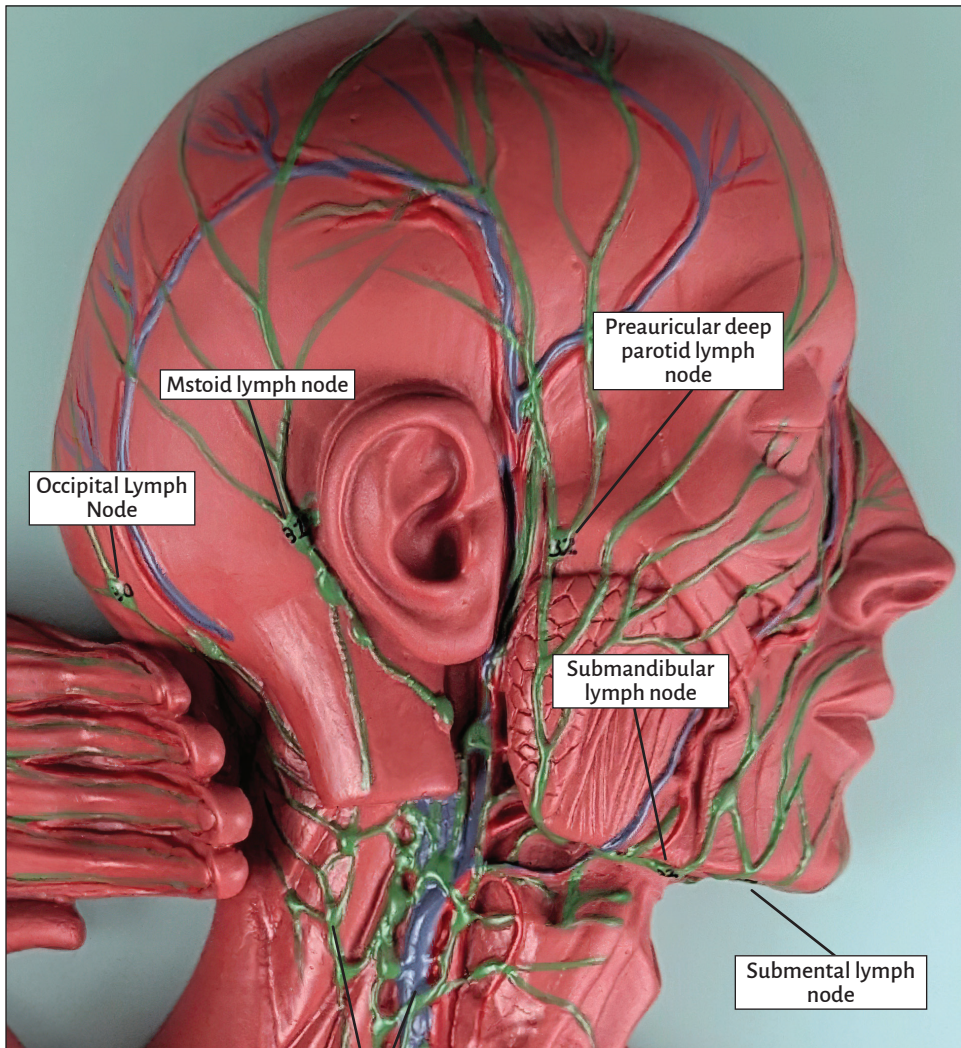


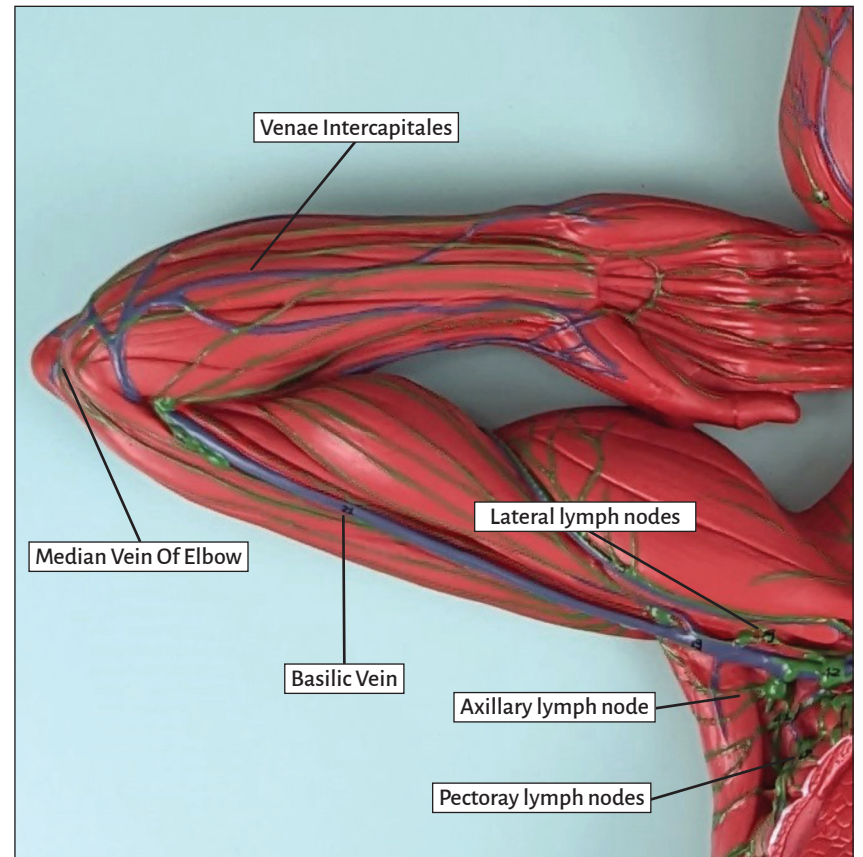


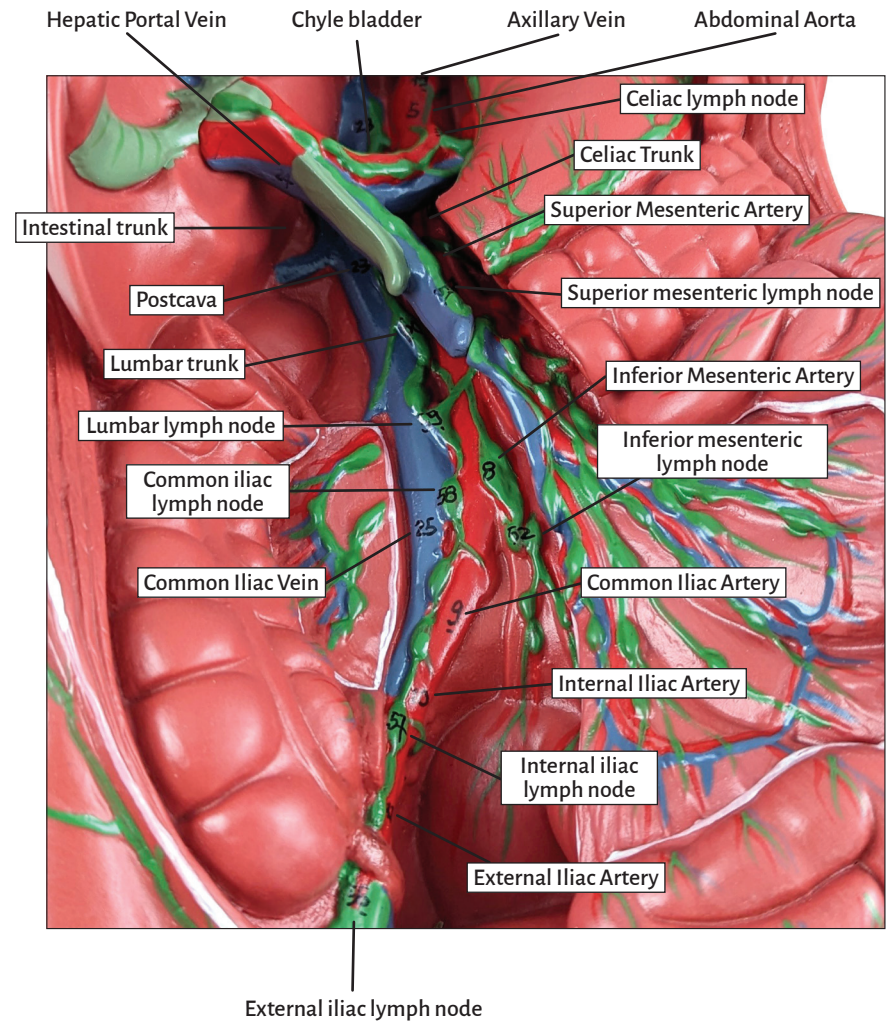
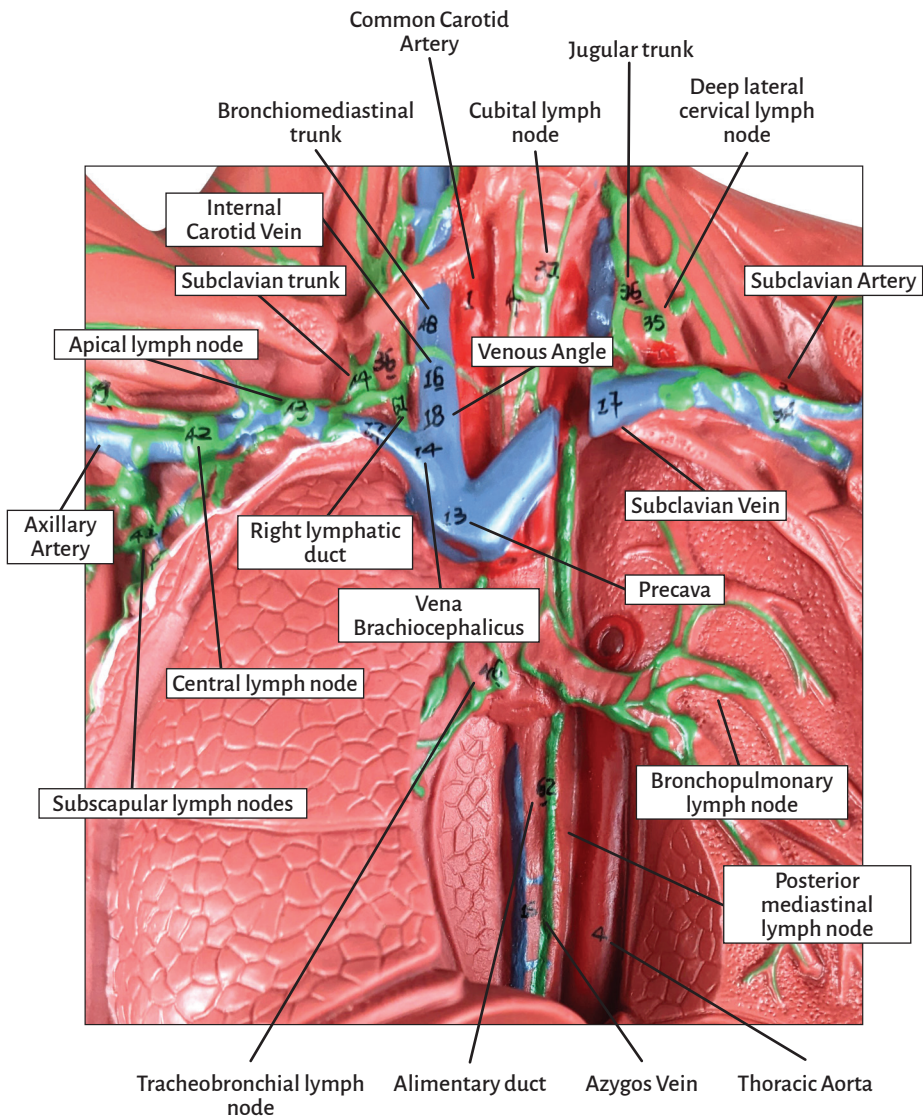
Axis Scientific Human Lymphatic System

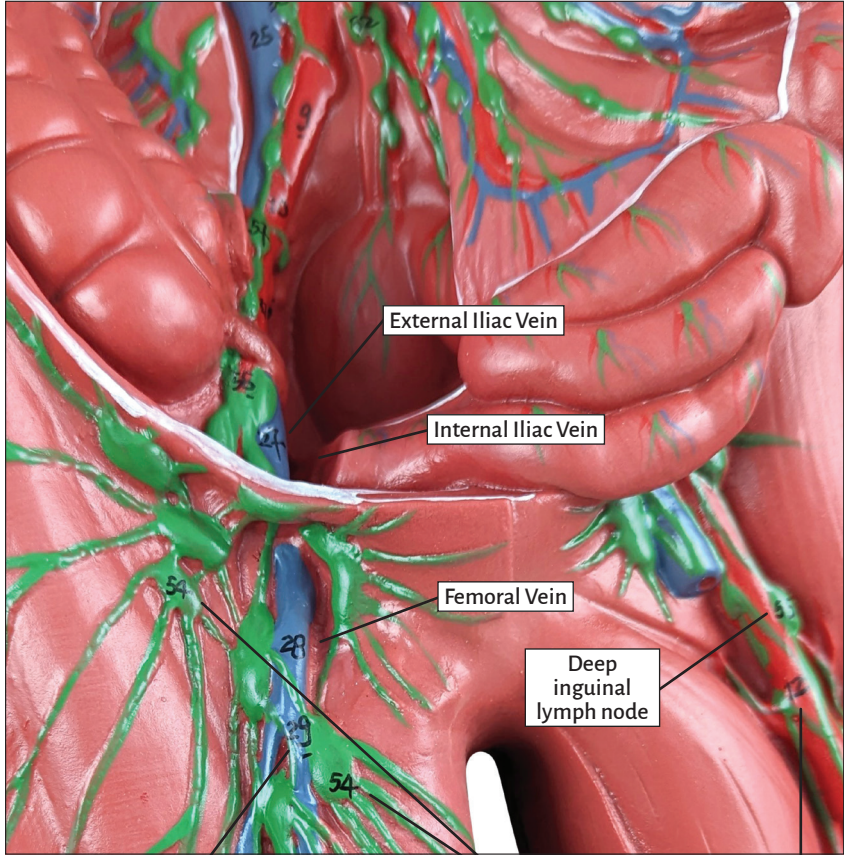
A-109161



Paratracheal lymph node







External Iliac Vein

Internal Iliac Vein

Femoral Vein

Deep
inguinal
lymph node

Great Saphenous Vein

Superficial inguinal lymph node

Femoral Artery



Human Lymphatic System

Arteries & Vena

Common carotid artery
Subclavian artery
Axillary artery
Thoracic aorta
Abdominal aorta
Celiac trunk
Superior mesenteric artery
Inferior mesenteric artery
Common iliac artery
Internal iliac artery
External iliac artery
Femoral artery
Precava
Vena brachiocephalicus
Azygos vein
Internal carotid vein
Subclavian vein
Venous angle
Axillary vein
Venae intercapitales
Basilic vein
Median vein of elbow
Postcava

Hepatic portal vein
Common iliac vein
Internal iliac vein
External iliac vein
Femoral vein
Great saphenous vein

Partial Lymph Nodes

Occipital lymph node
Mstoid lymph node
Preauricular deep parotid lymph node
Submandibular lymph node
Submental lymph node
Deep lateral cervical lymph node
Jugular trunk
Cubital lymph node
Axillary lymph node
Lateral lymph nodes
Pectoray lymph nodes
Subscapular lymph nodes
Central lymph node
Apical lymph node
Subclavian trunk

Thoracic Lymph Nodes

Bronchopulmonary lymph node
Tracheobronchial lymph node
Paratracheal lymph node
Bronchiomediastinal trunk
Posterior mediastinal lymph node

Impar Organs Lymph Nodes

Celiac lymph node
Superior mesenteric lymph node
Inferior mesenteric lymph node
Intestinal trunk

Lymph Nodes in Even Organs, Pelvis and Lower Limbs.

Superficial inguinal lymph node
Deep inguinal lymph node
External iliac lymph node
Internal iliac lymph node
Common iliac lymph node
Lumbar lymph node
Lumbar trunk
Right lymphatic duct
Alimentary duct
Chyle bladder

