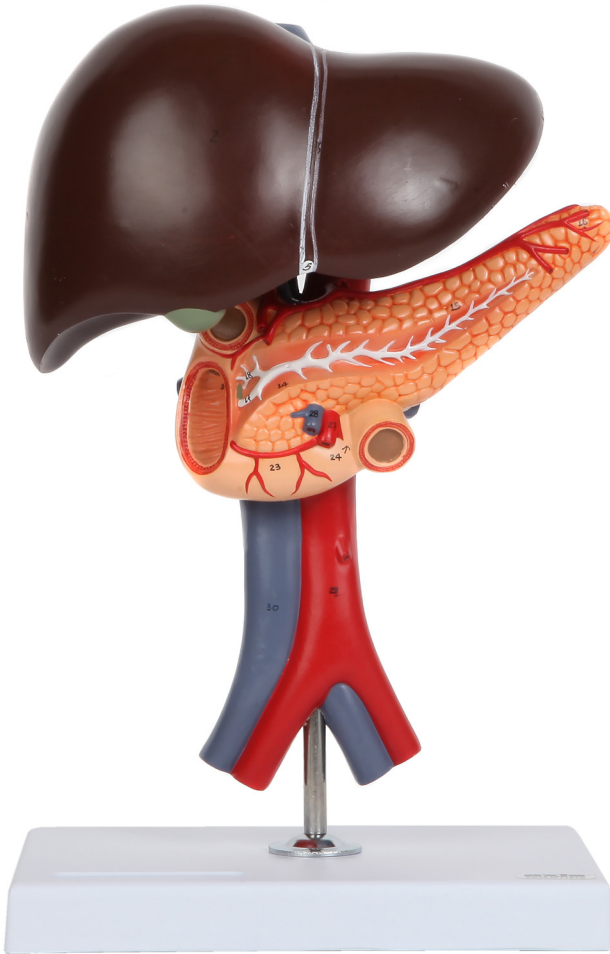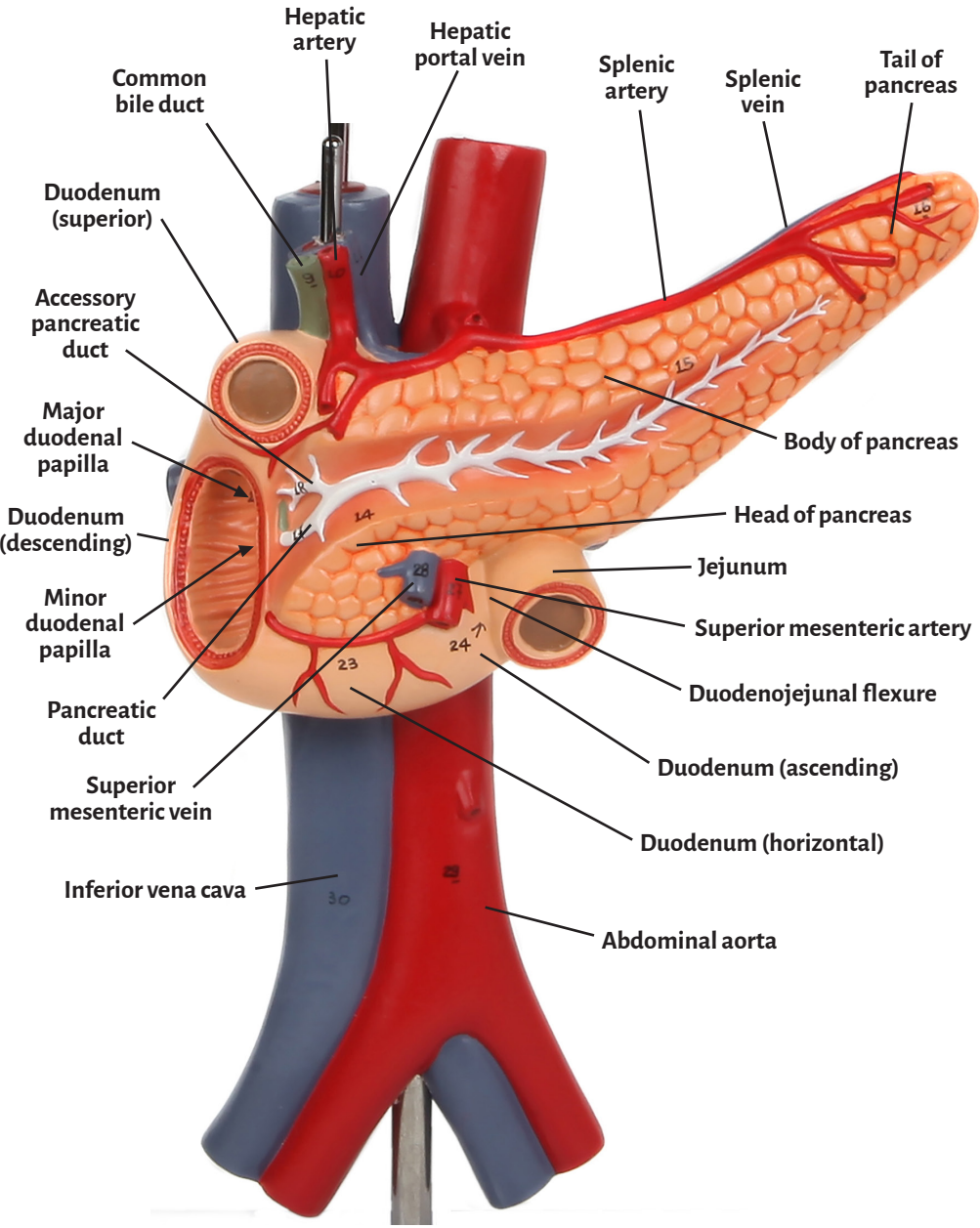


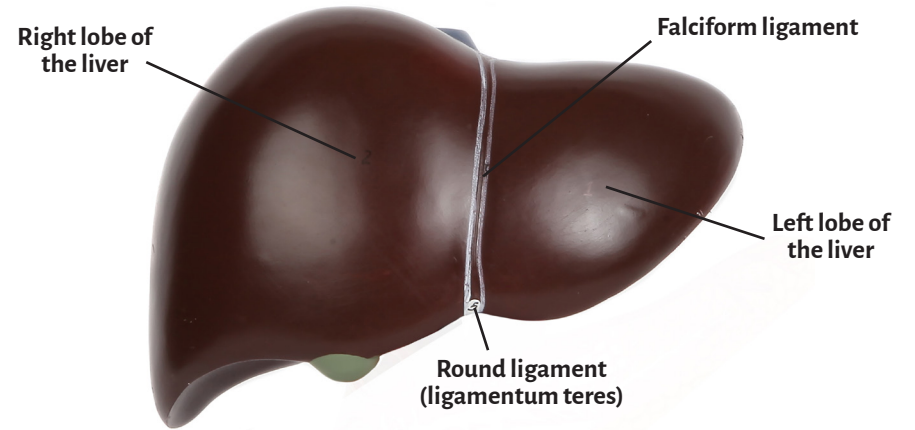
Axis Scientific Human Digestive System Model - Liver, Pancreas and Duodenum

A-109168

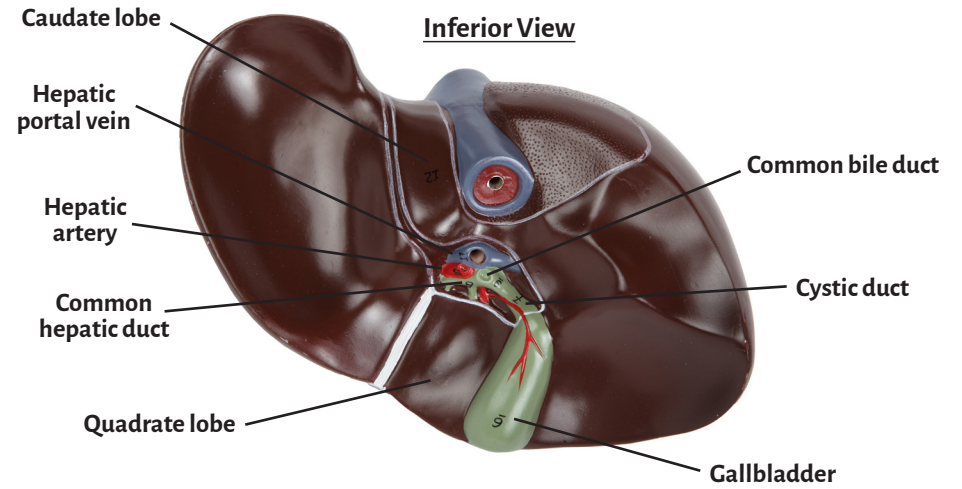
Anterior View



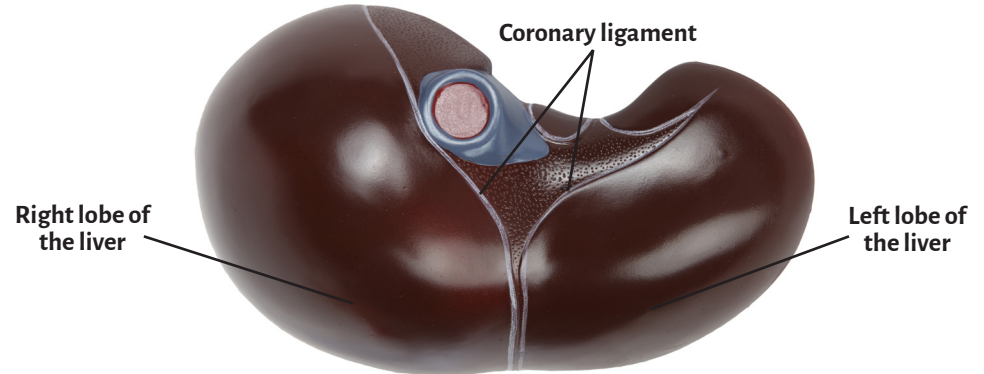
Anterior View



Inferior View



Superior View





Abdominal aorta	Hepatic artery
Accessory pancreatic duct	Hepatic portal vein
Body of pancreas	Inferior vena cava
Caudate lobe	Jejunum
Common bile duct	Left lobe of the liver
Common hepatic duct	Major duodenal papilla
Coronary ligament	Minor duodenal papilla
Cystic duct	Pancreatic duct
Duodenojejunal flexure	Quadrangle lobe
Duodenum (ascending)	Right lobe of the liver
Duodenum (descending)	Round ligament (ligamentum teres)
Duodenum (horizontal)	Splenic artery
Duodenum (superior)	Splenic vein
Falciform ligament	Superior mesenteric artery
Gallbladder	Superior mesenteric vein
Head of pancreas	Tail of pancreas

