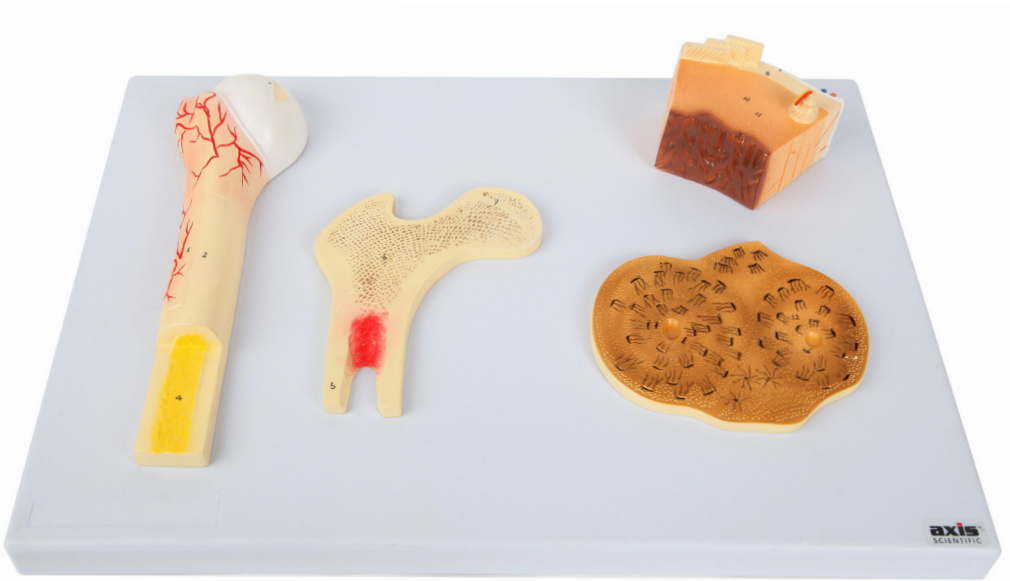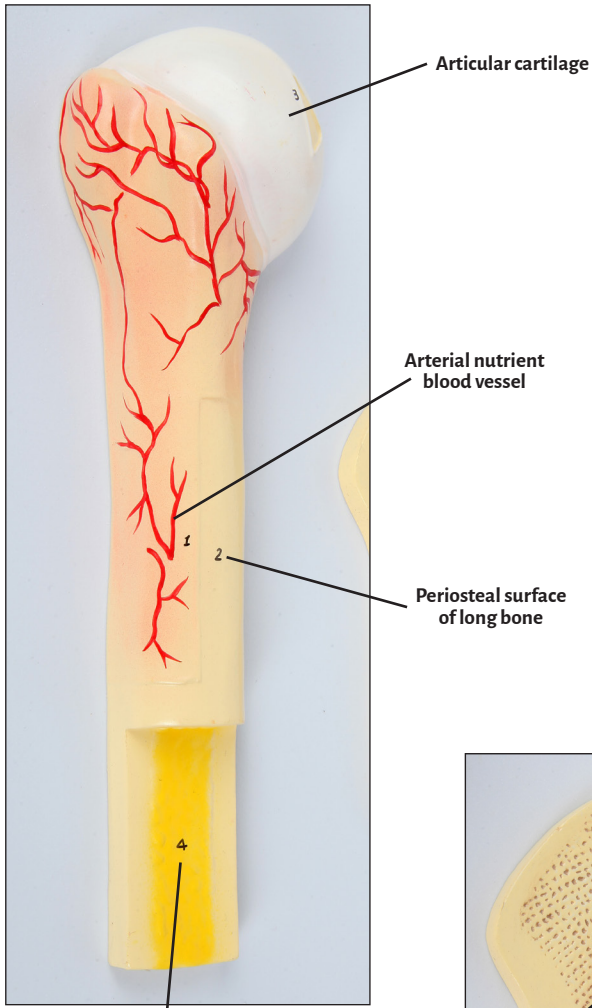


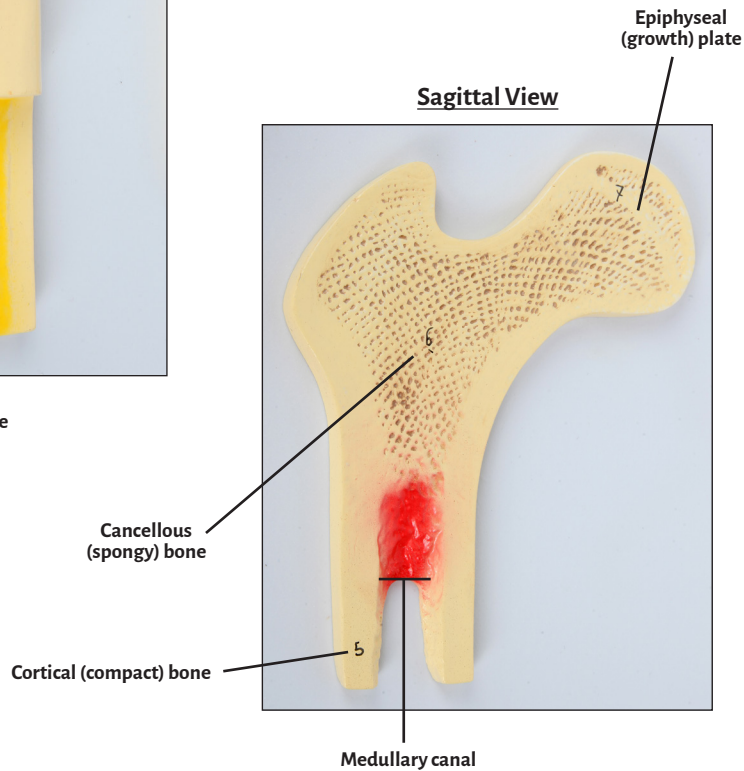
Axis Scientific Human Bone Microstructure with Long Bone Osteon

A-109186

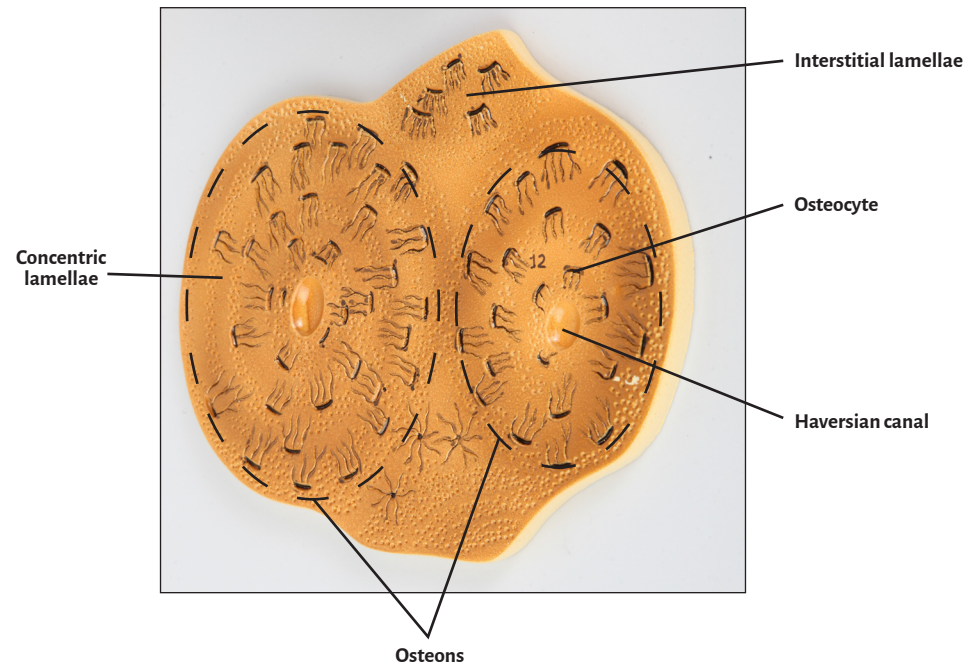
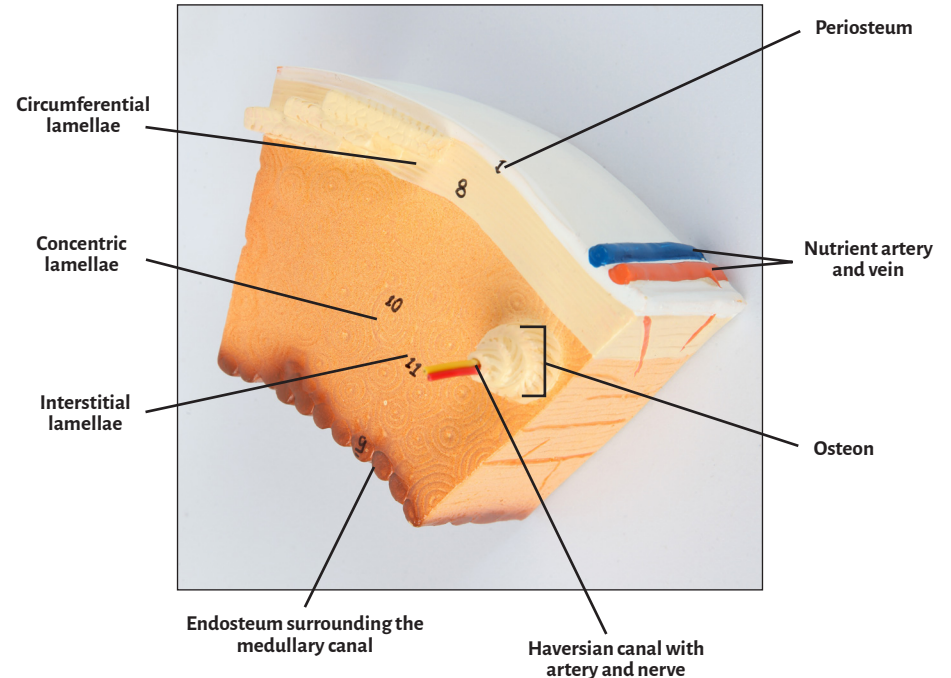
Anterior View



Sagittal View



Cross-Sectional View





Articular cartilage

Interstitial lamellae

Arterial nutrient blood vessel

Medullary canal

Cancellous (spongy) bone

Nutrient artery and vein

Circumferential lamellae

Osteocyte

Concentric lamellae

Osteon

Cortical (compact) bone

Osteons

Endosteum surrounding the medullary canal

Periosteal surface of long bone

Epiphyseal (growth) plate

Haversian canal

Periosteum

Haversian canal with artery and nerve

Yellow bone marrow

