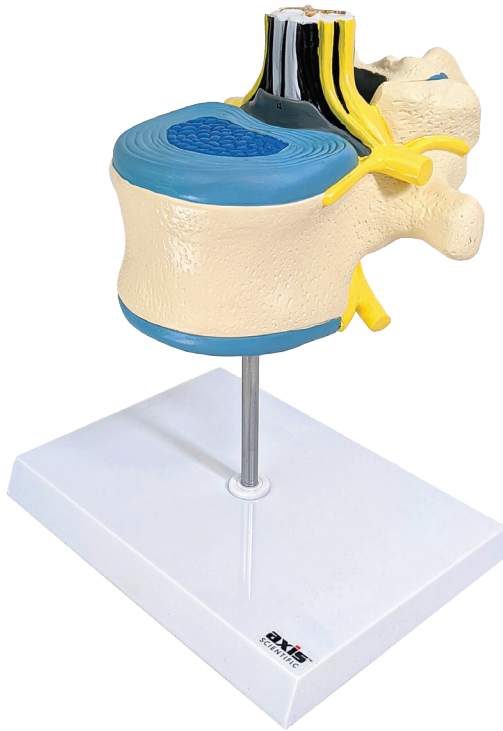

---

**axis**<sup>TM</sup>  
SCIENTIFIC



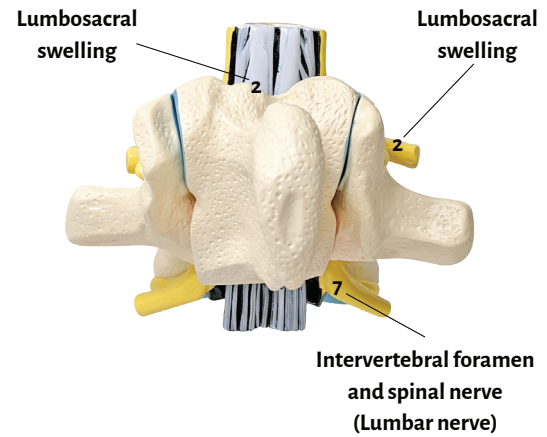
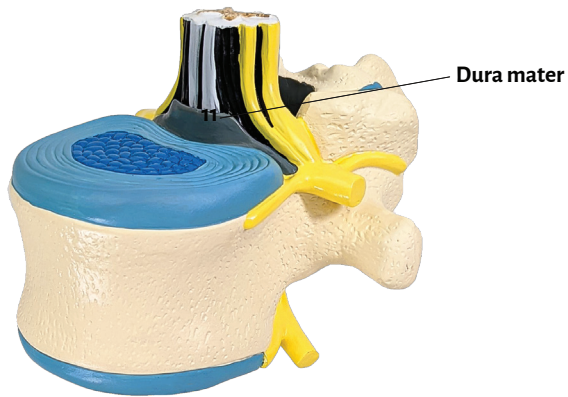
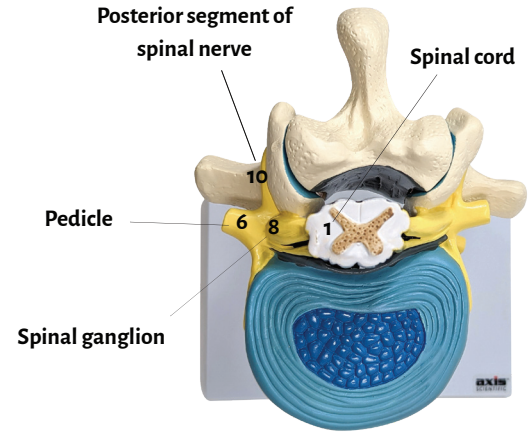
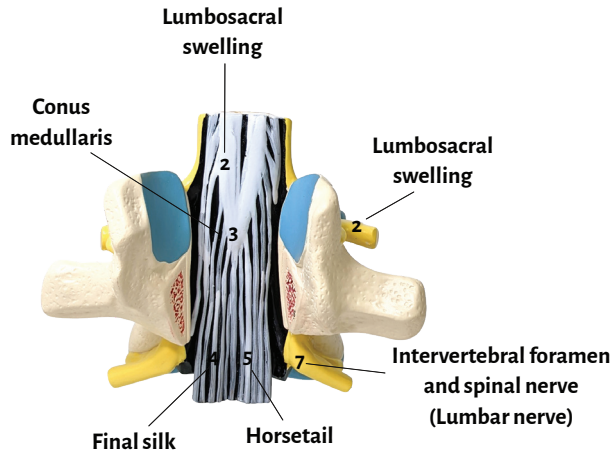
---

**Axis Scientific Thoracic Vertebrae with Spinal Cord and Spinal Nerve**

---

A-111940

---





Spinal cord

Intervertebral foramen and spinal nerve  
(Lumbar nerve)

Lumbosacral swelling

Spinal ganglion

Conus medullaris

Final silk

Horsetail

Pedicle

Anterior segment of spinal nerve

Posterior segment of spinal nerve

Dura mater



© 2020 AXIS SCIENTIFIC