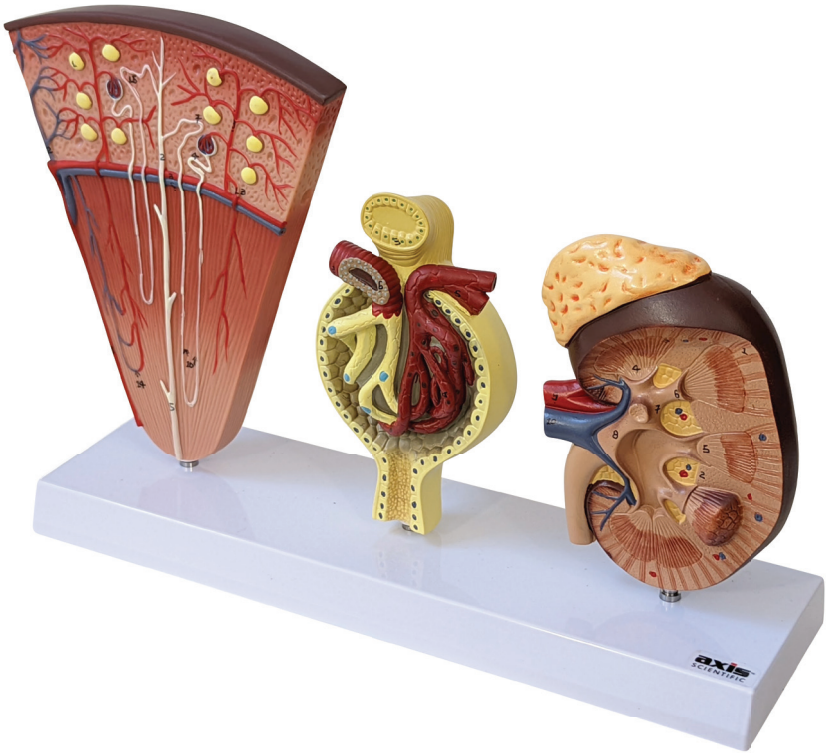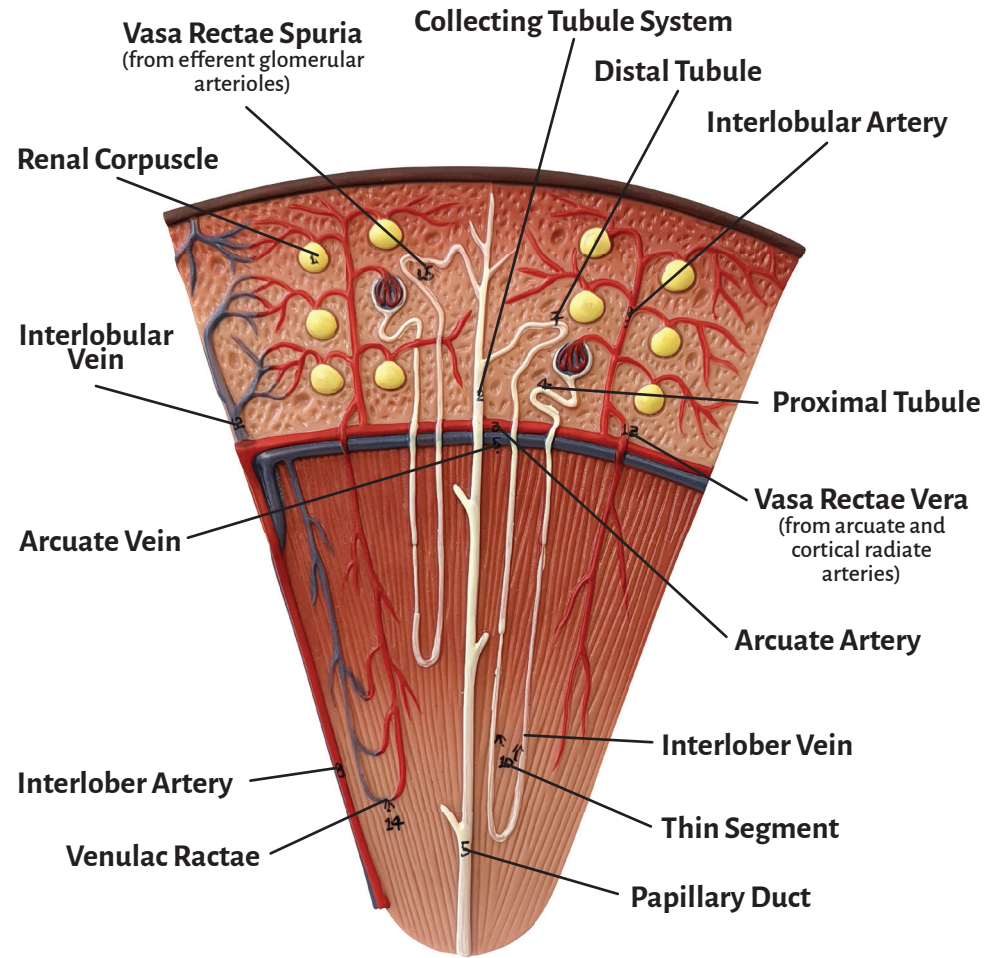
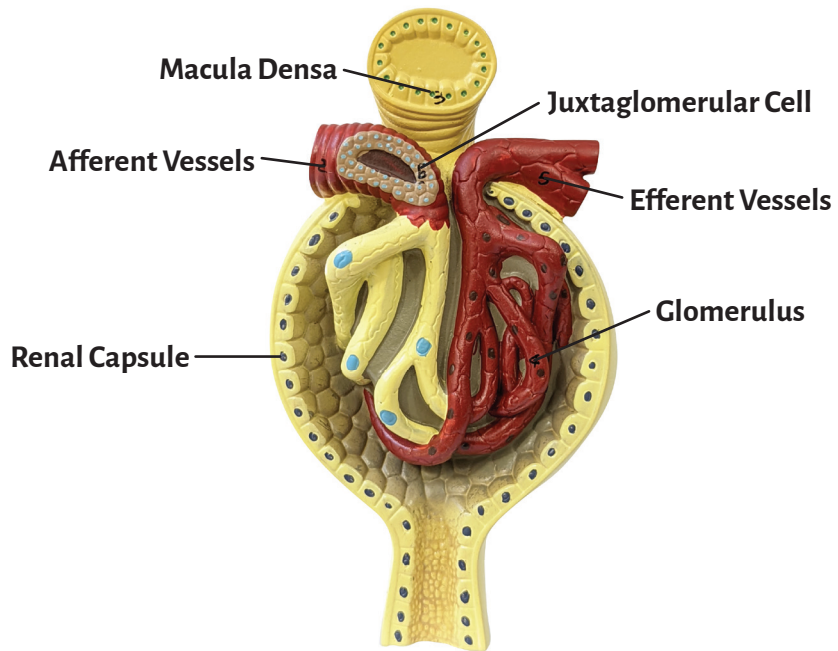
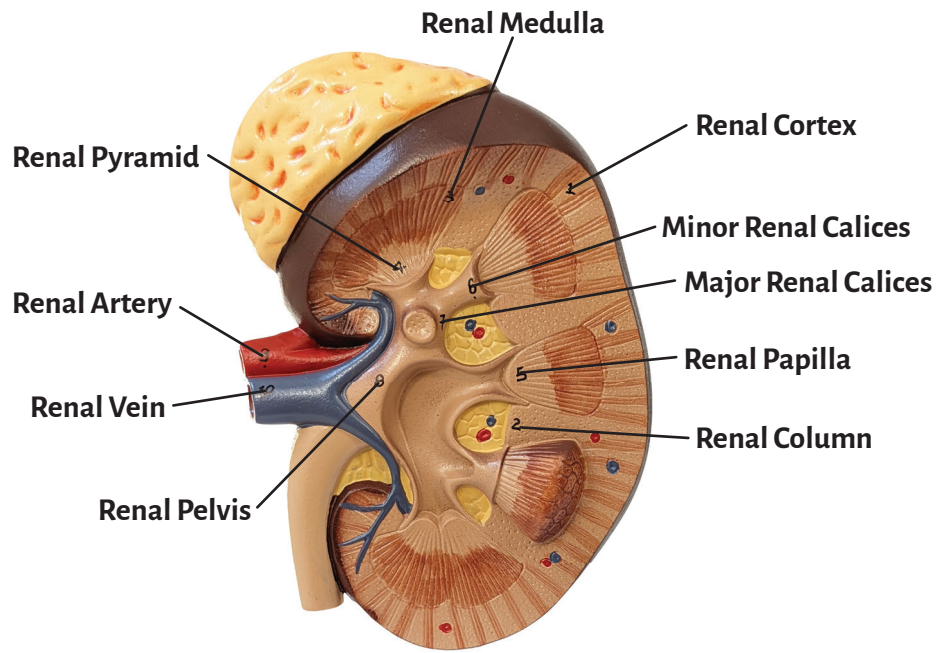




**Axis Scientific Kidney, Nephron and Glomerulus**

**A-111943**





## **Kidney**

Renal Cortex

Renal Column

Renal Medulla

Renal Pyramid

Renal Papilla

Minor Renal Calices

Major Renal Calices

Renal Pelvis

Renal Artery

Renal Vein

## **Nephron**

Renal Corpuscle

Collecting Tubule System

Arcuate Artery

Proximal Tubule

Papillary Duct

Arcuate Vein

Distal Tubule

Interlobar Artery

Interlobular Artery

Thin Segment

Interlobar Vein

Interlobular Vein

**Vasa Rectae Vera**  
(from arcuate and cortical radiate arteries)

**Venulac Ractae**

**Vasa Rectae Spuria**  
(from efferent glomerular arterioles)

## **Glomerulus**

Renal Capsule

Afferent Vessels

Macula Densa

Glomerulus

Efferent Vessels

Juxtaglomerular Cell

